

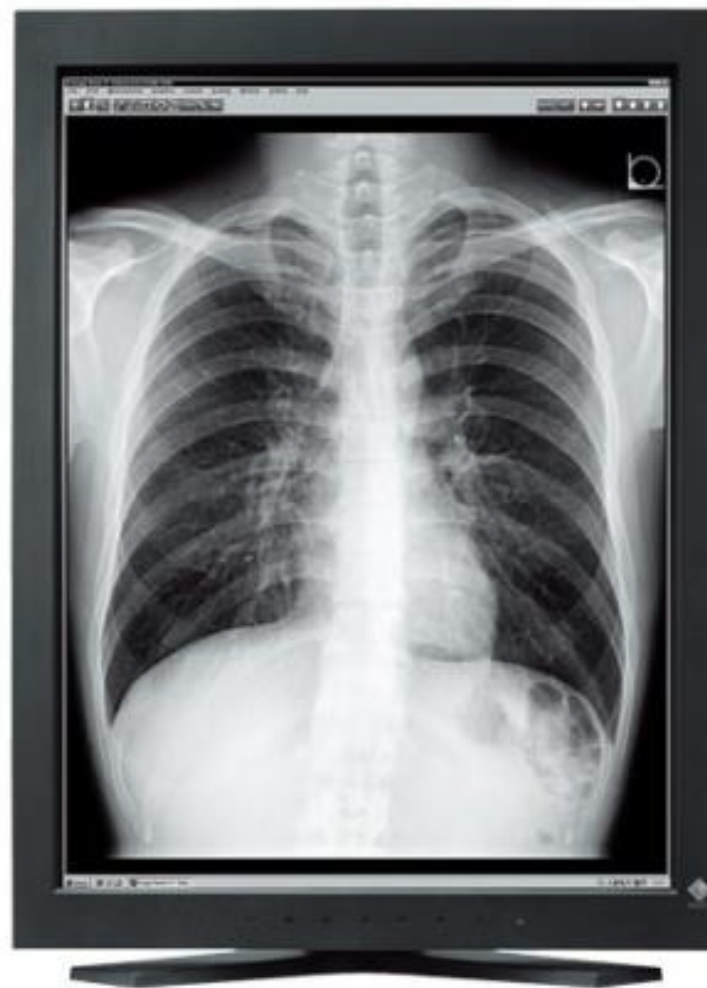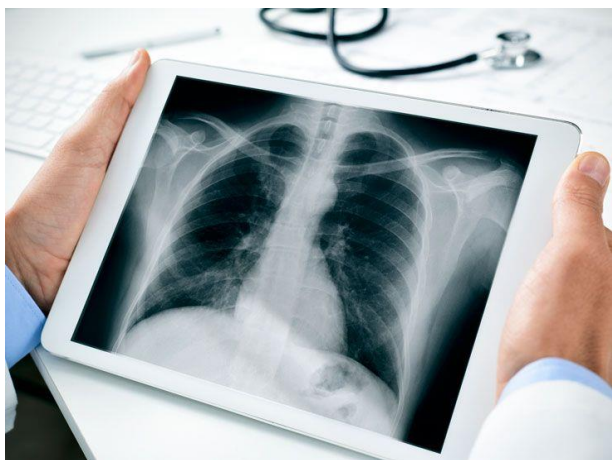
Chest X-ray for the Non-Radiologist: Revisiting Chest X-ray Interpretation

~~LOOK CLOSLEY~~

Tim Gilmore, PhD, RRT, RRT-NPS, RRT-ACCS, AE-C, CPFT
Program Director; Associate Professor
Cardiopulmonary Science
LSUHS School of Allied Health Professions

Objectives

- **Overview universal x-ray concepts**
- **Explore various clinical implications of chest x-ray findings**
- **Practice identification of key items during chest x-ray interpretation**

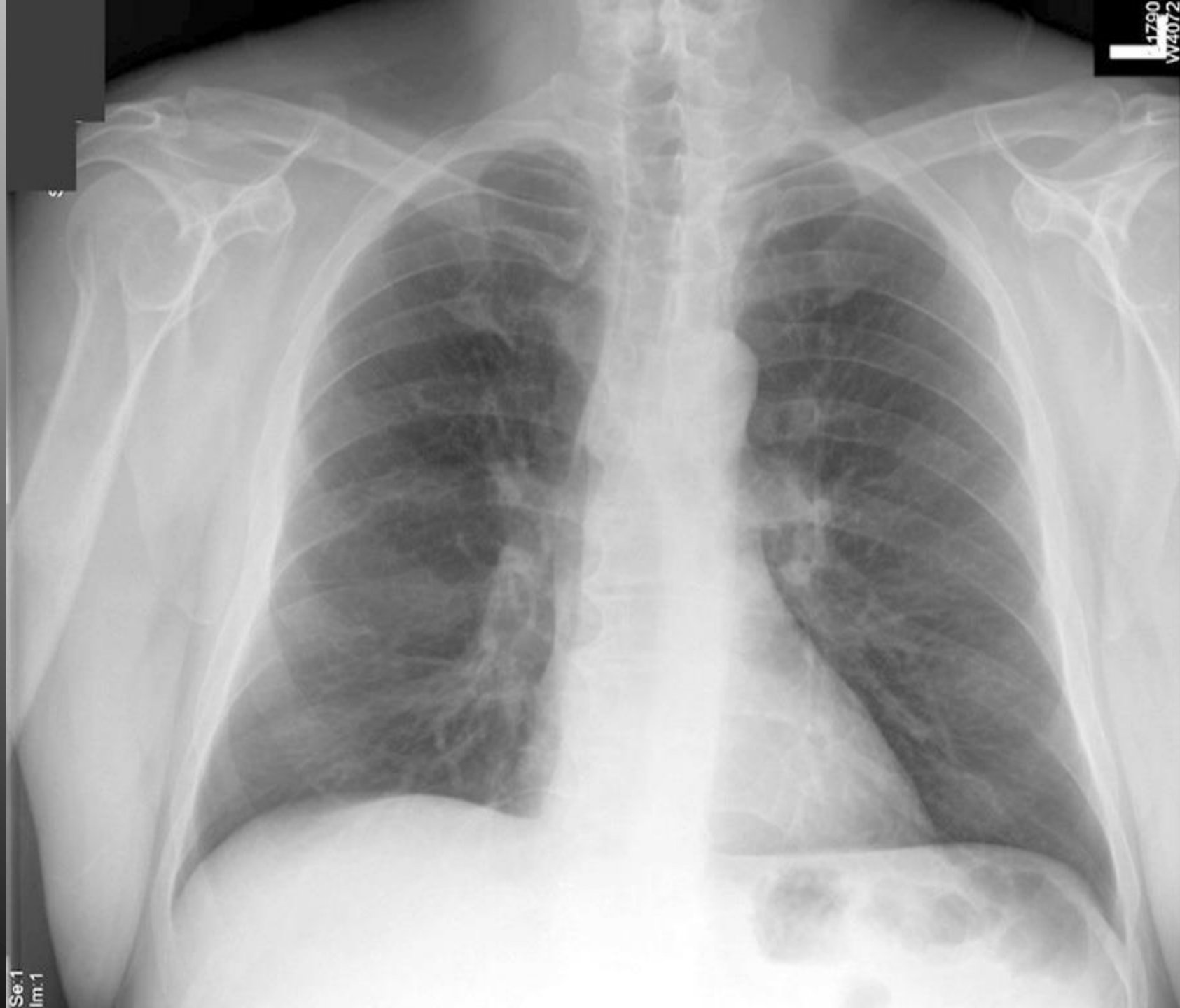

Log On

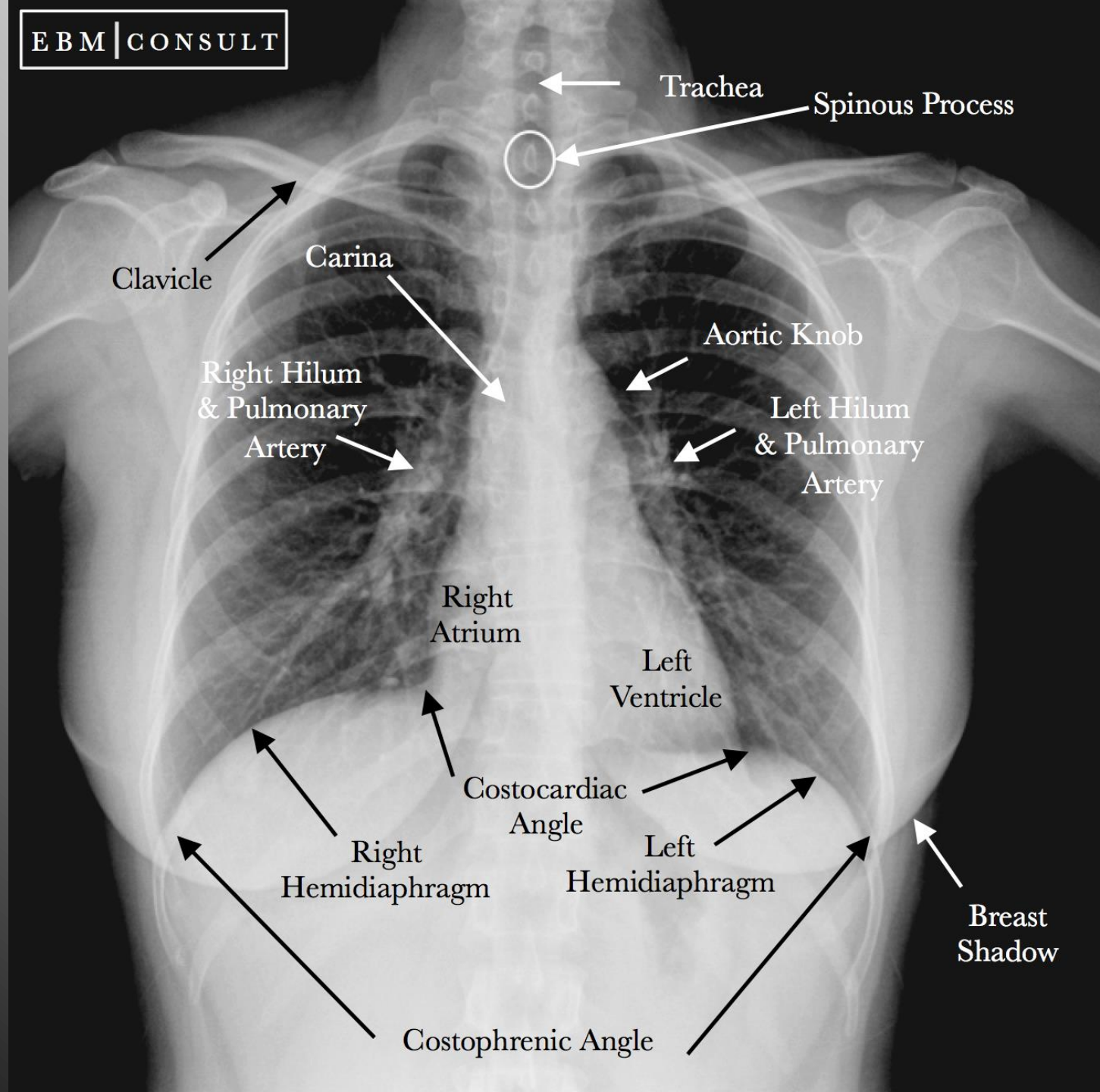
* User Name

* Password

Se:1
Im:1



1790
W4072



Trachea

Spinous Process

Clavicle

Carina

Right Hilum
& Pulmonary
Artery

Aortic Knob

Left Hilum
& Pulmonary
Artery

Right
Atrium

Left
Ventricle

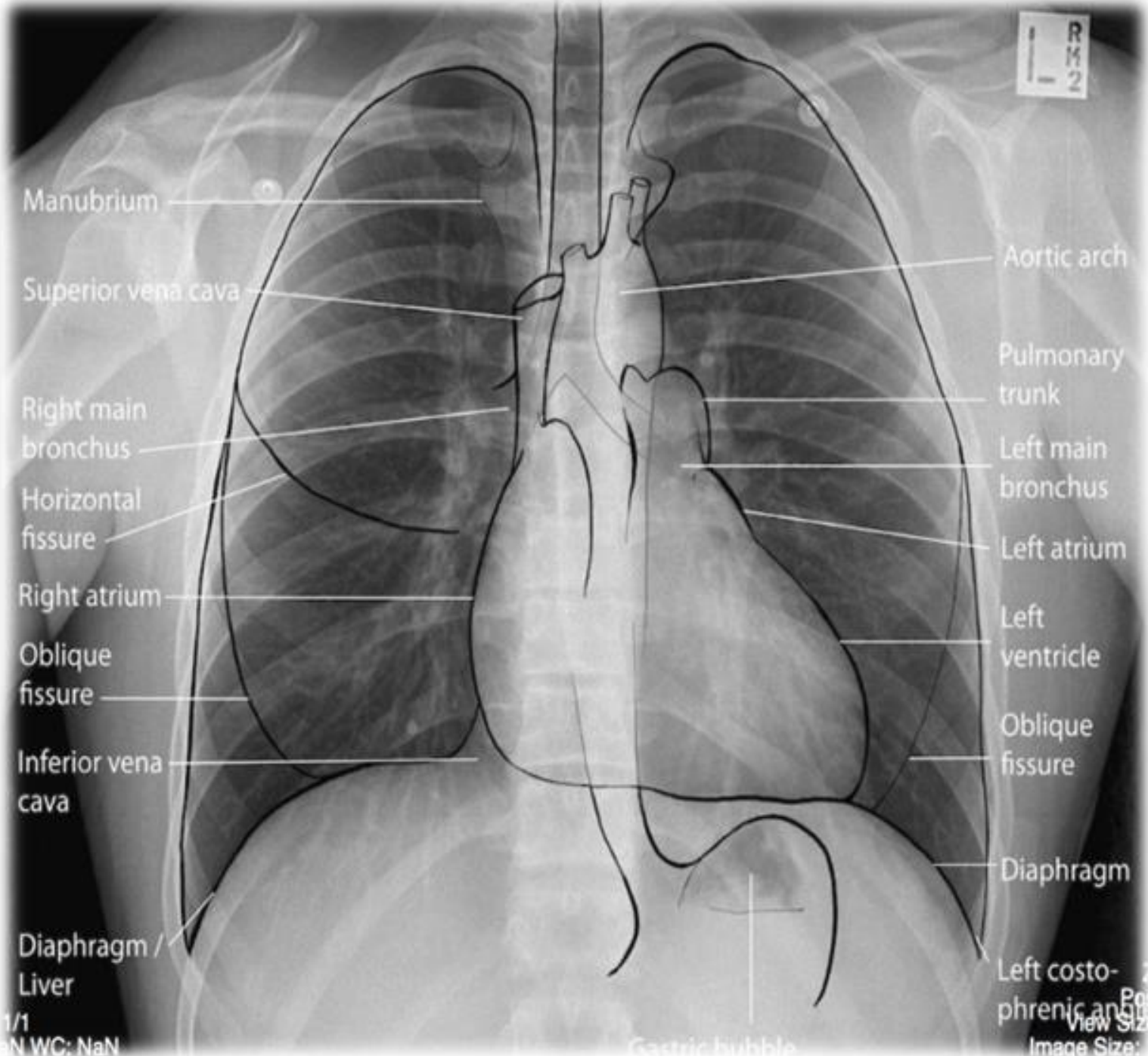
Costocardiac
Angle

Right
Hemidiaphragm

Left
Hemidiaphragm

Breast
Shadow

Costophrenic Angle



Manubrium

Superior vena cava

Right main bronchus

Horizontal fissure

Right atrium

Oblique fissure

Inferior vena cava

Diaphragm / Liver

Aortic arch

Pulmonary trunk

Left main bronchus

Left atrium

Left ventricle

Oblique fissure

Diaphragm

Left costo-phrenic angle

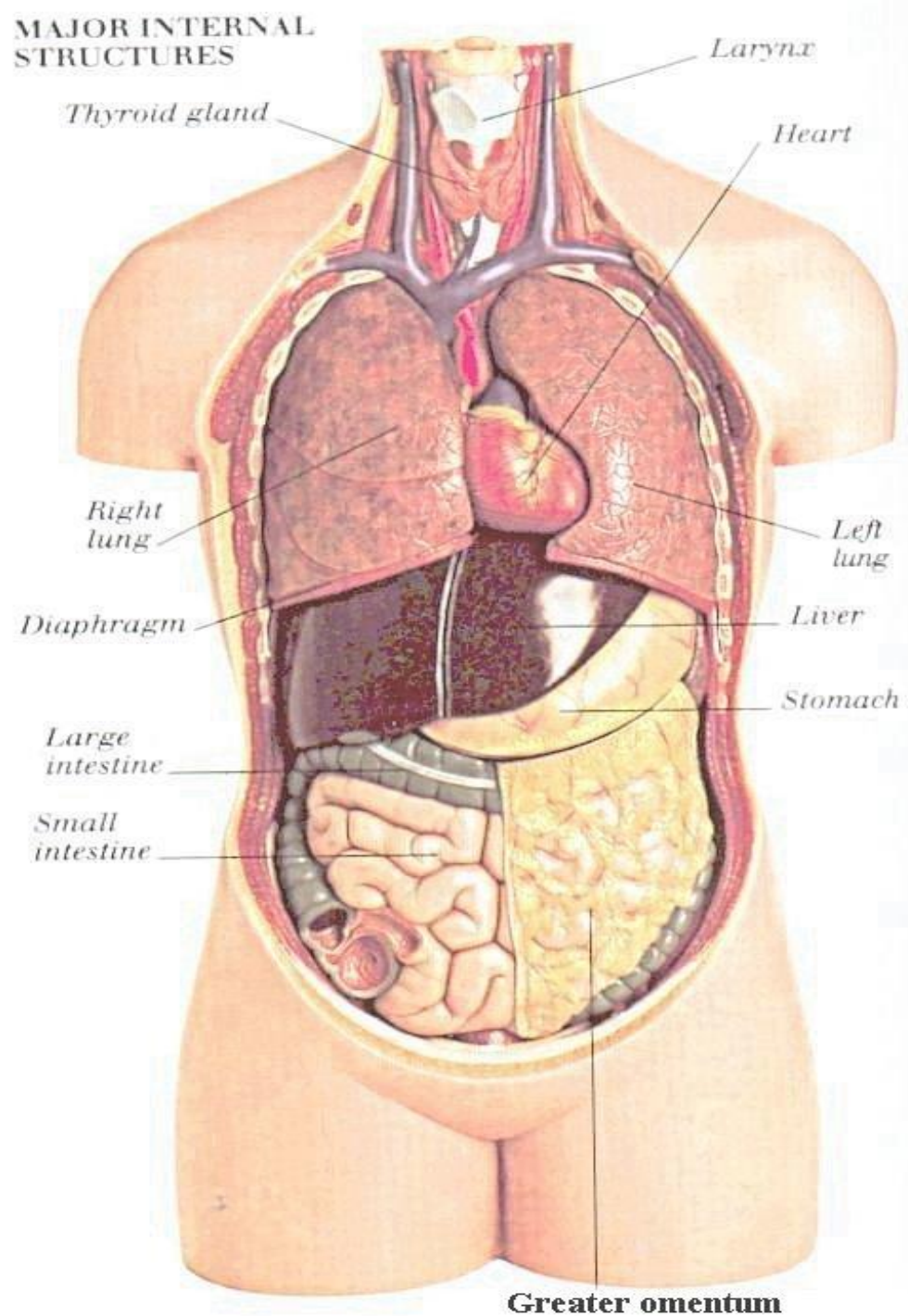
Gastric bubble

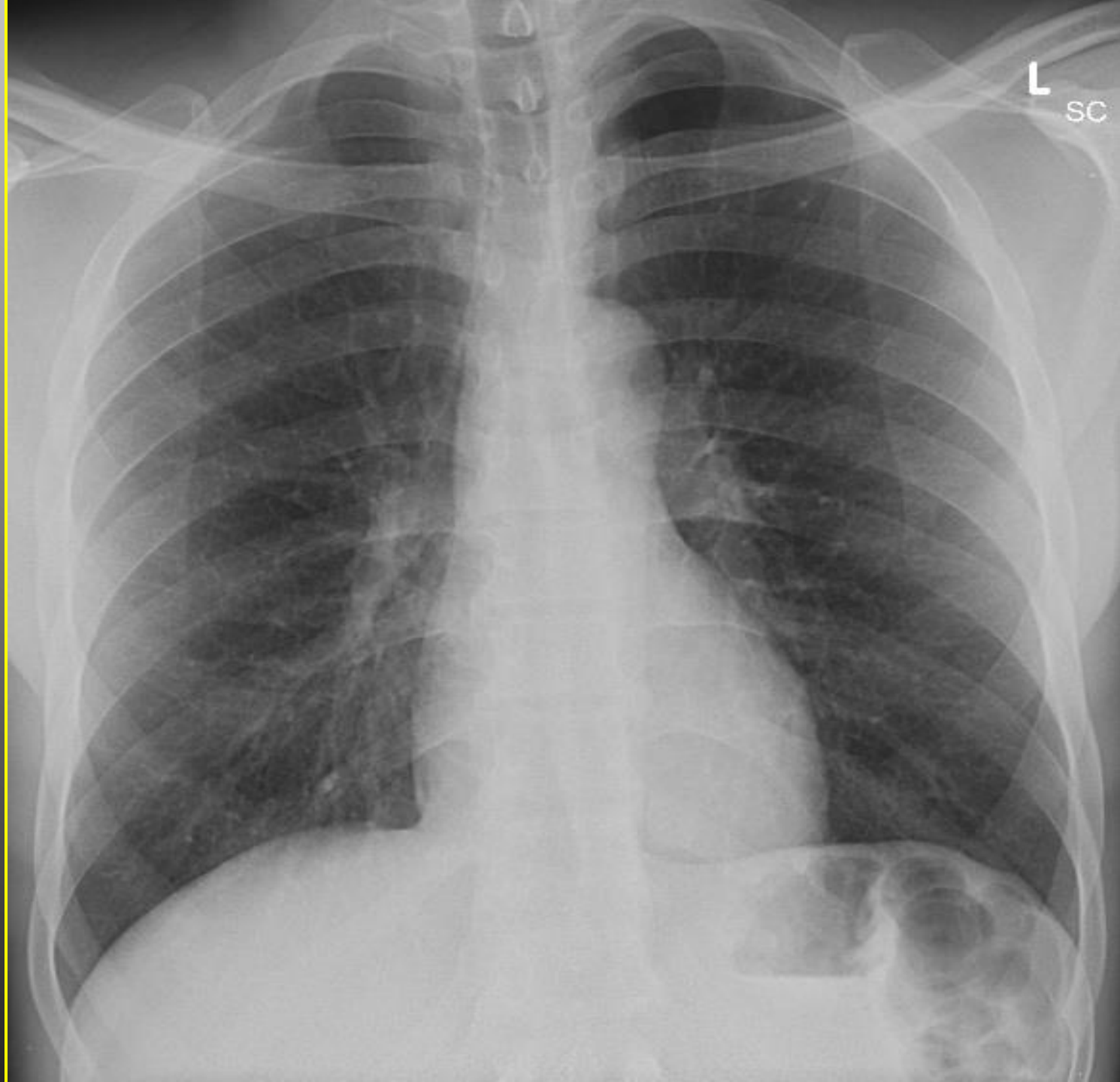
Systematic Evaluation

- **A** – Airway & Adenopathy (midline, patent?)
- **B** – Bones (fractures?)
- **C** – Cardiac Silhouette (cardiothoracic ratio?)
- **D** – Diaphragm (contour, angles)
- **E** – Everything else (extrapleural)

Crausman, RS. *Chest* 1998; 113; 256-257

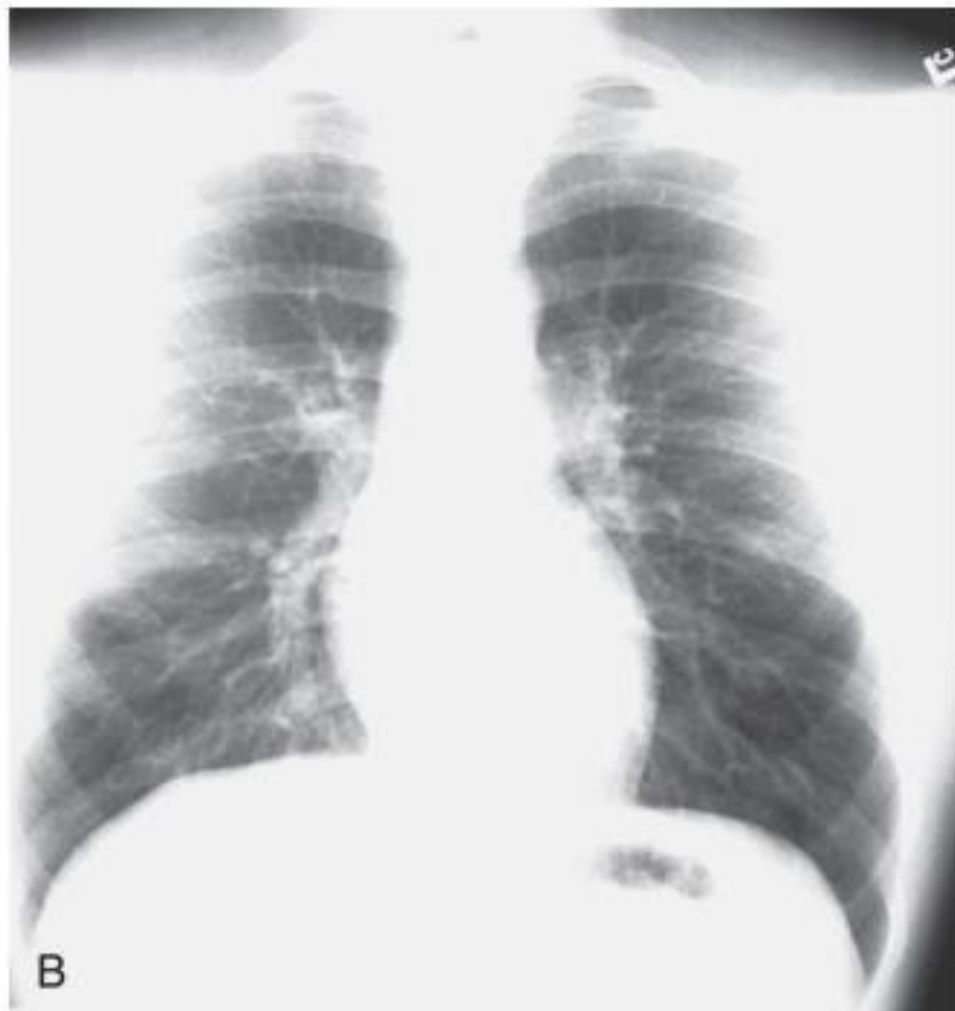
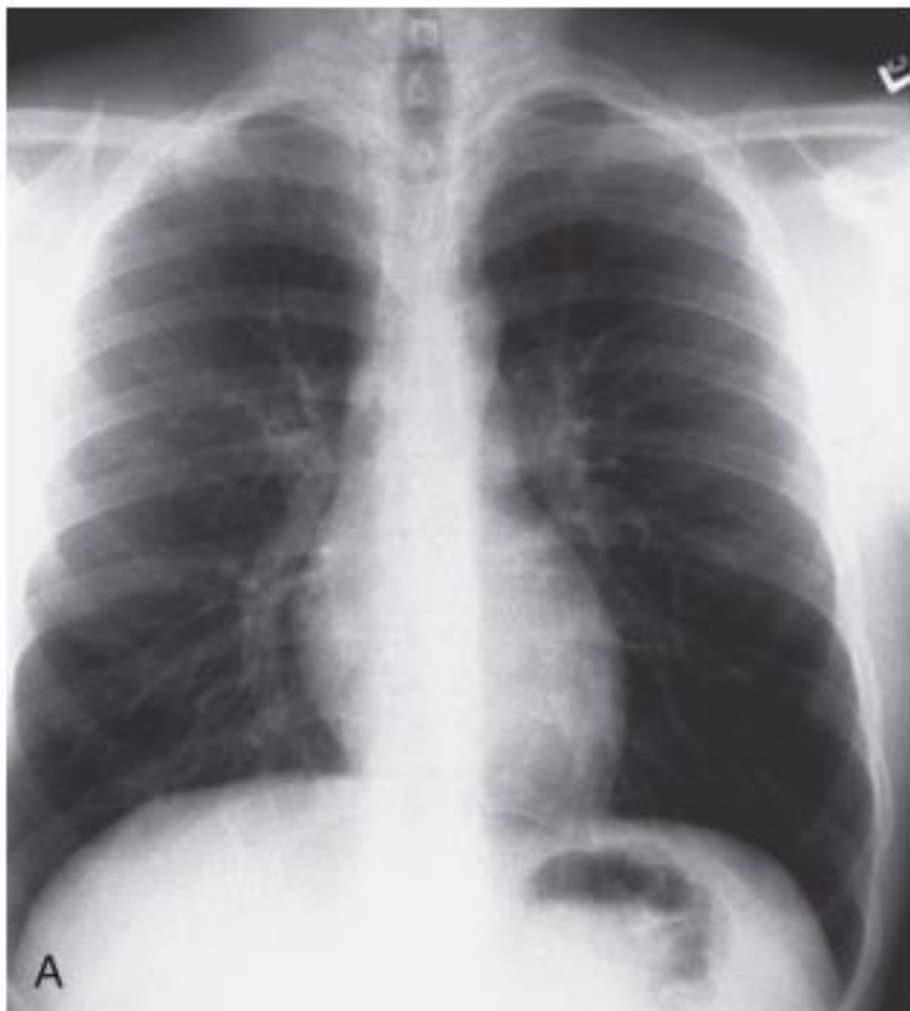Review of anatomy & landmarks





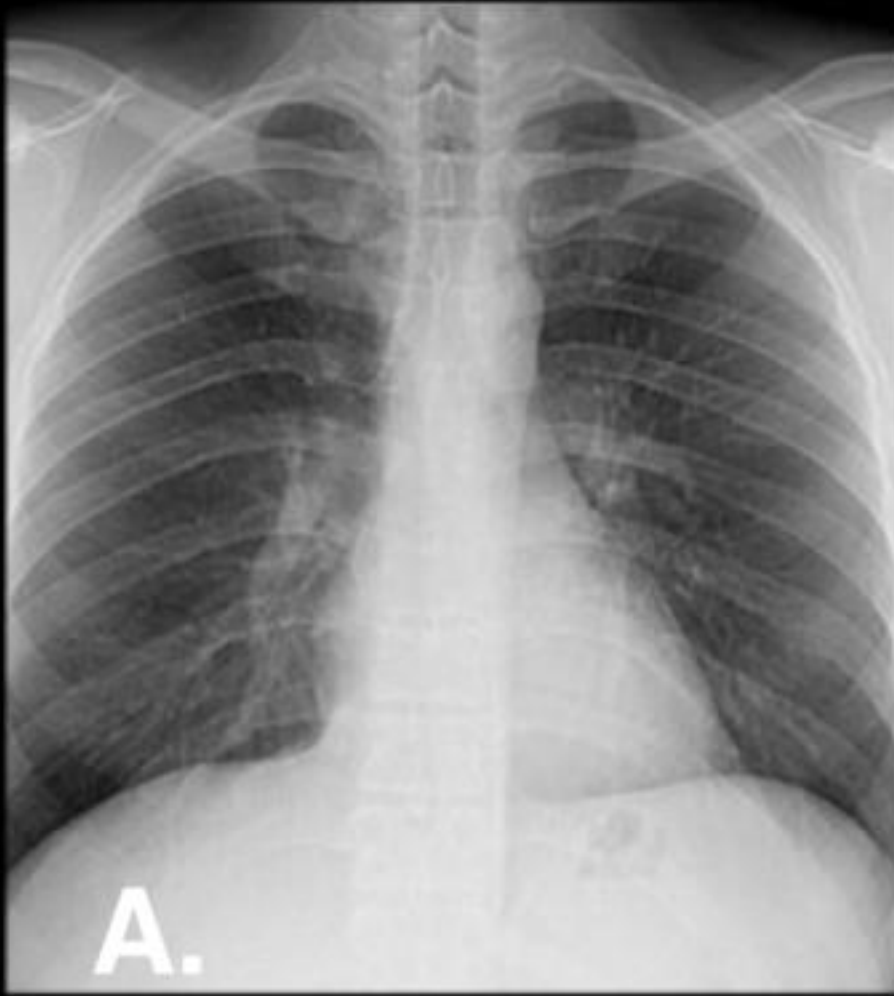
Overexposed

Underexposed

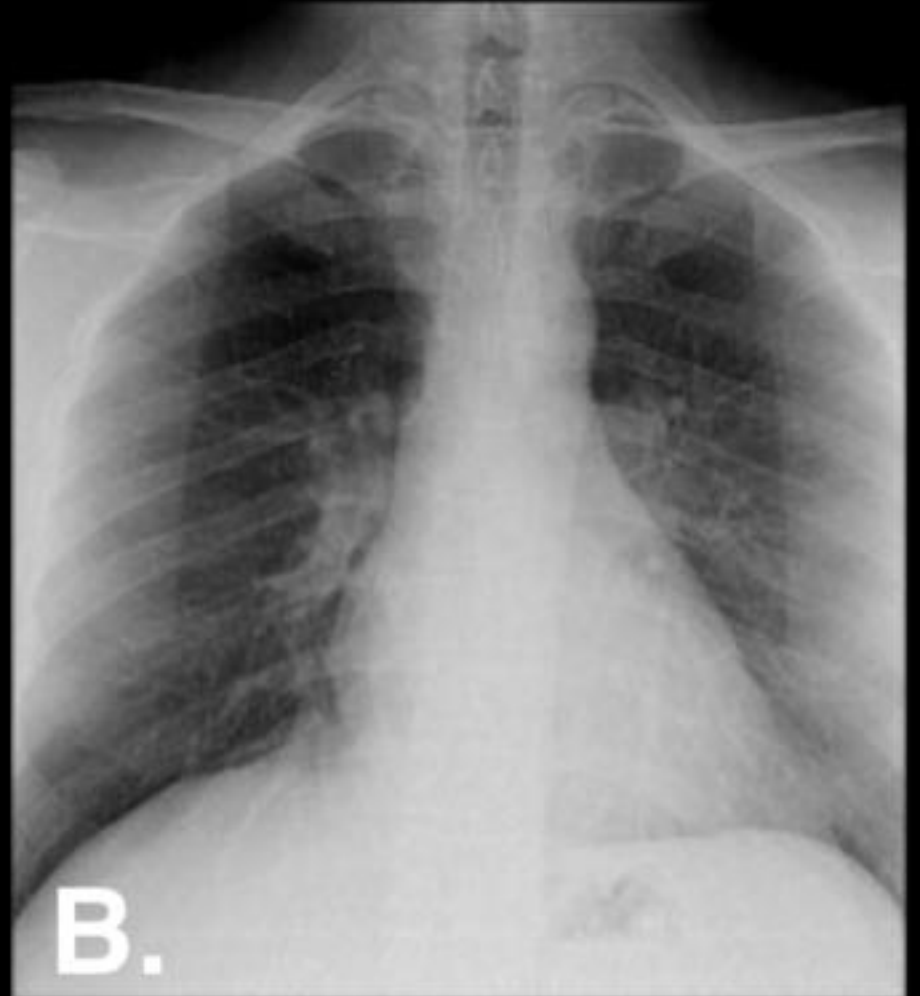


Patient Position?

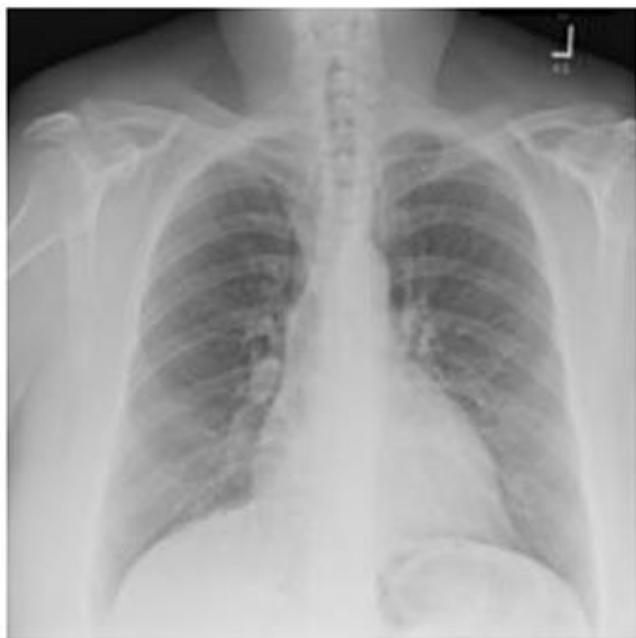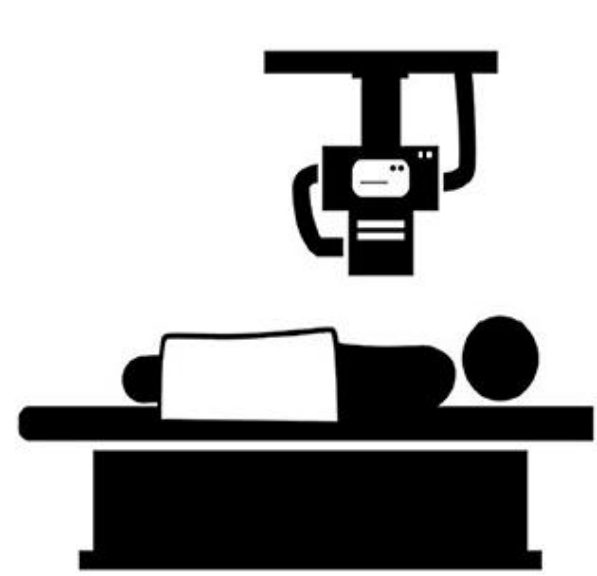- ❖ Anterior-posterior (AP)
- ❖ Posterior-anterior (PA)
- ❖ Left lateral decubitus (left side down)
- ❖ Right lateral decubitus (right side down)
- ❖ Oblique
 - ❖ Patient turned at an angle toward film



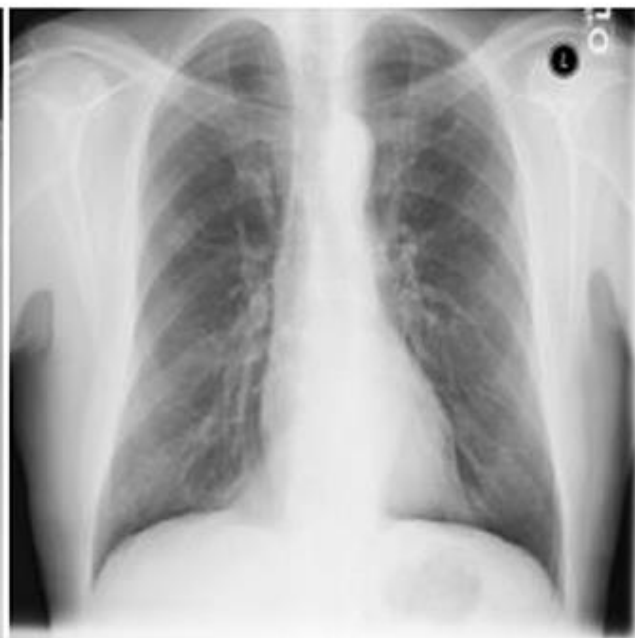Posterior **Anterior (PA)**



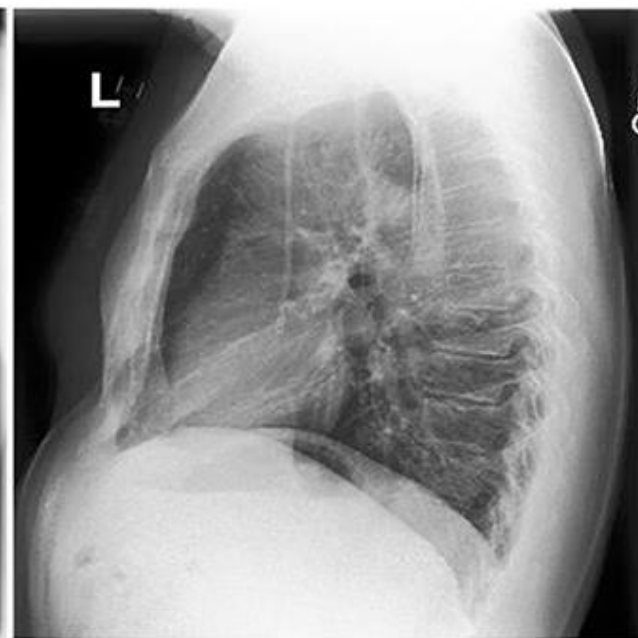
Anterior Posterior (AP)



A AP view

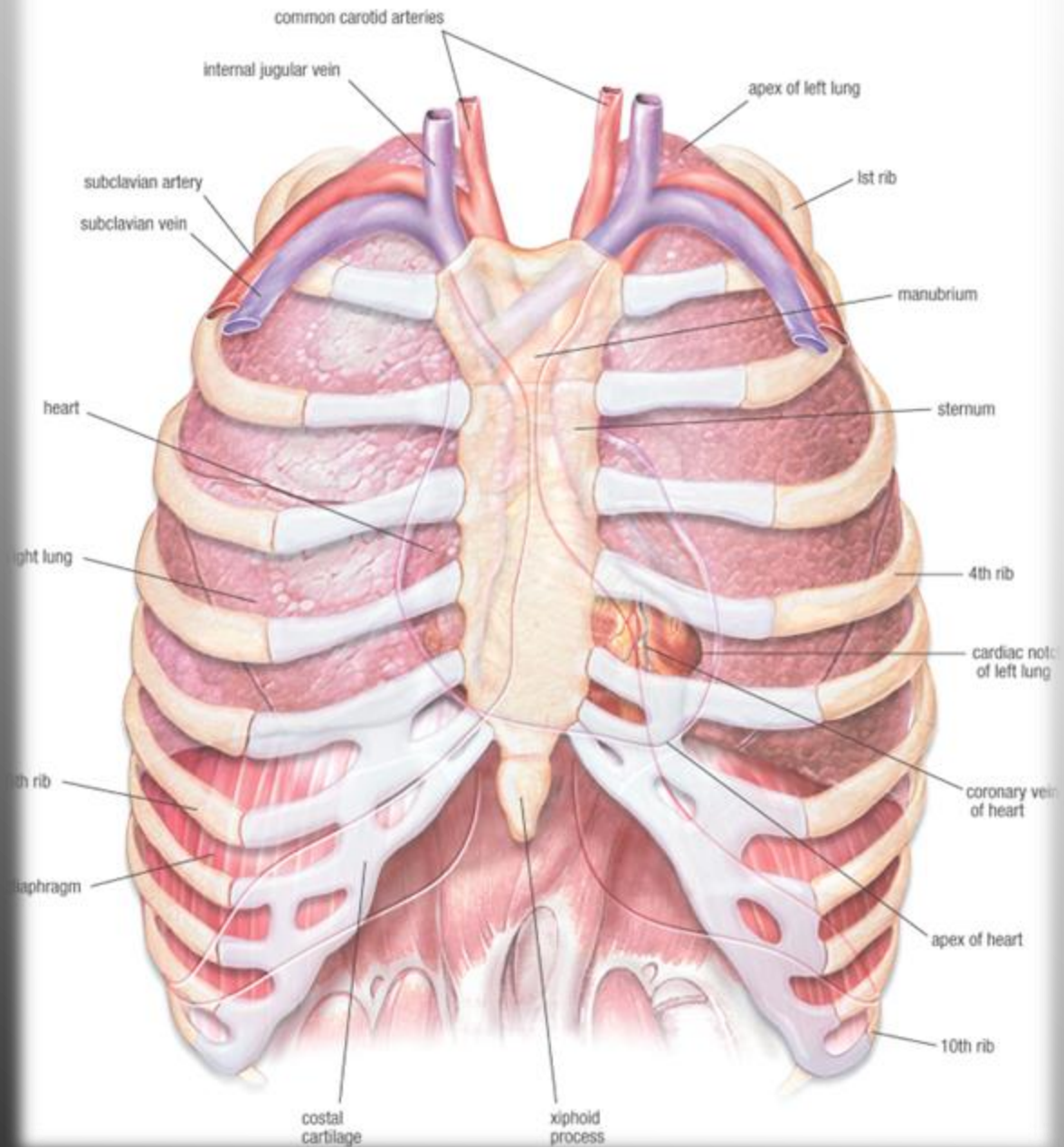


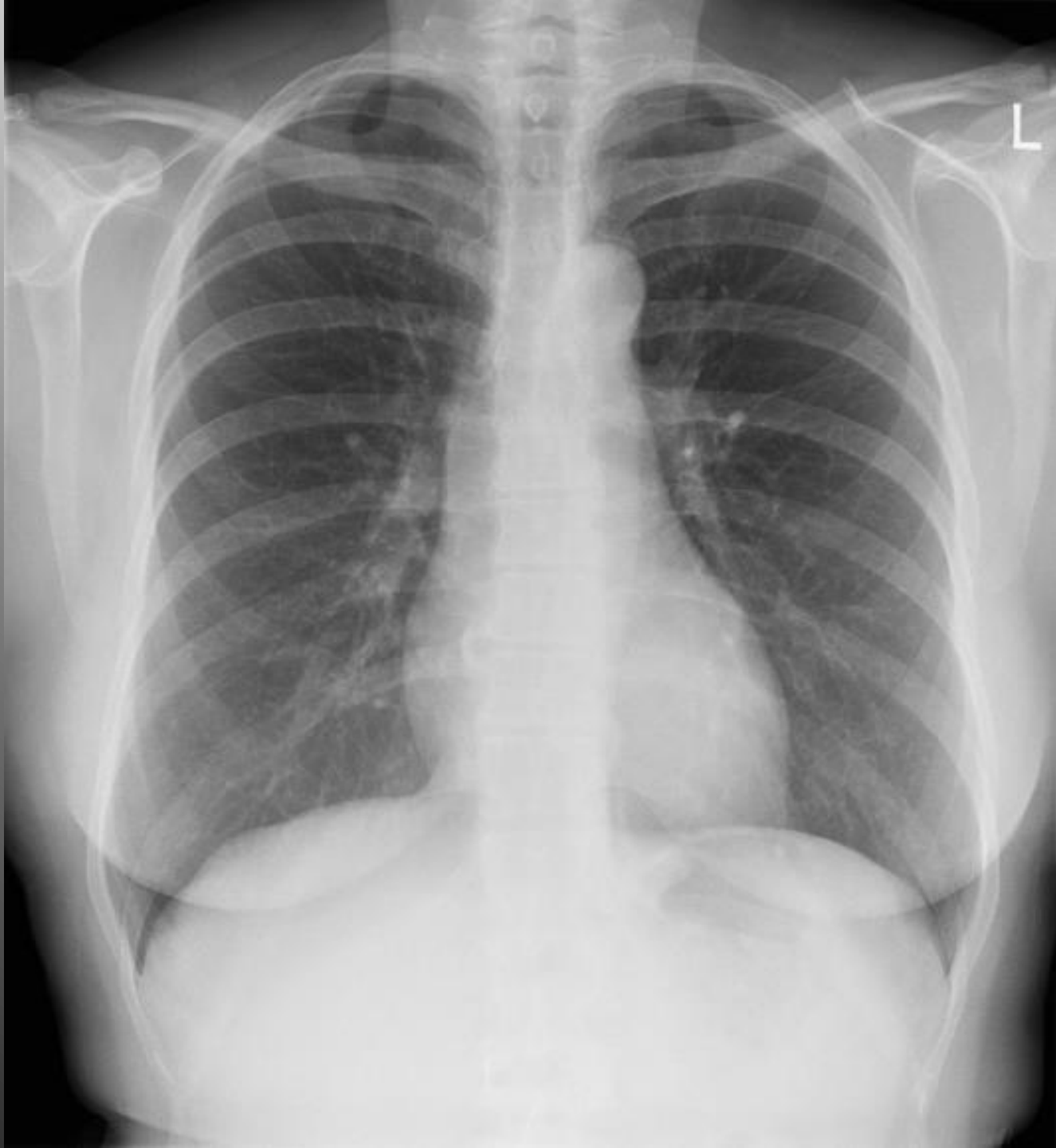B PA view

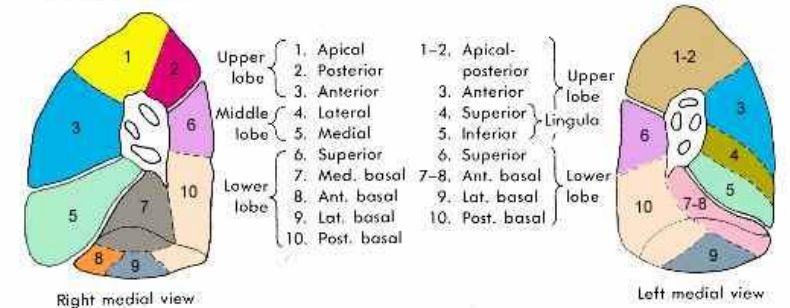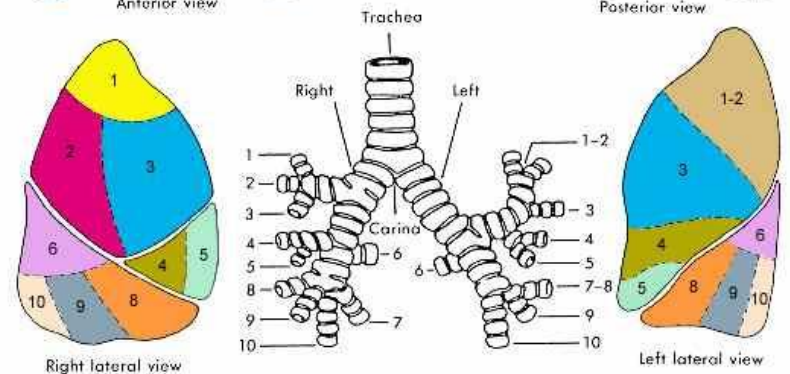
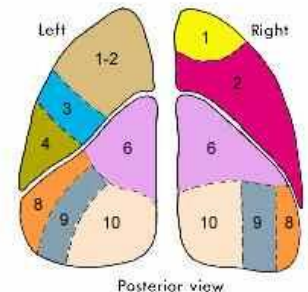
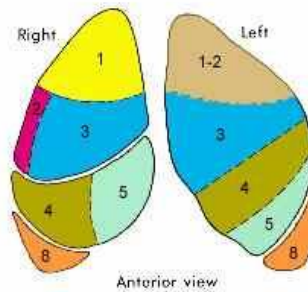
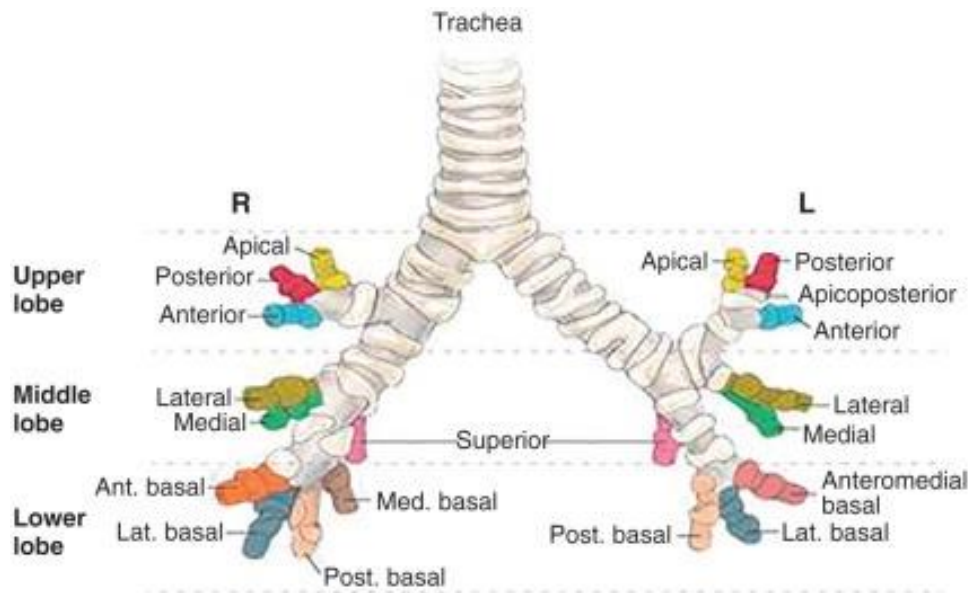


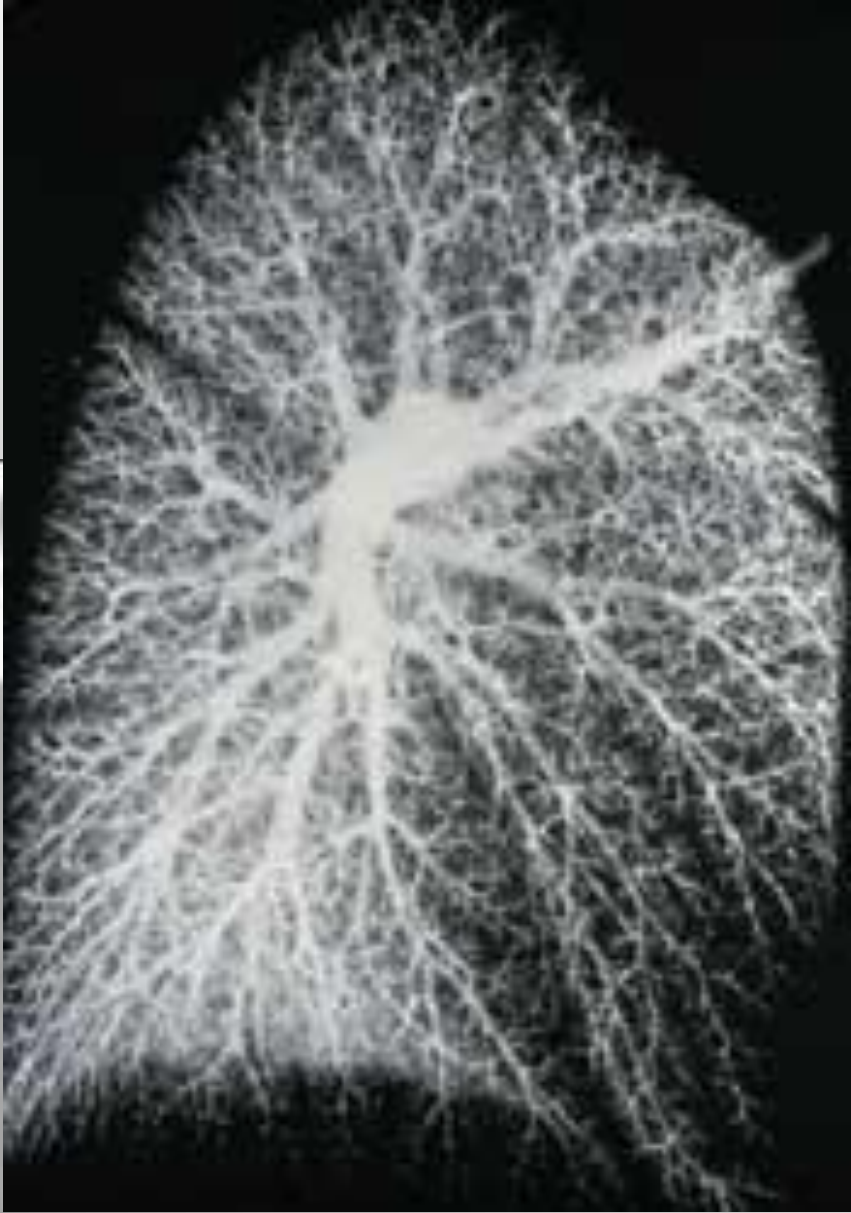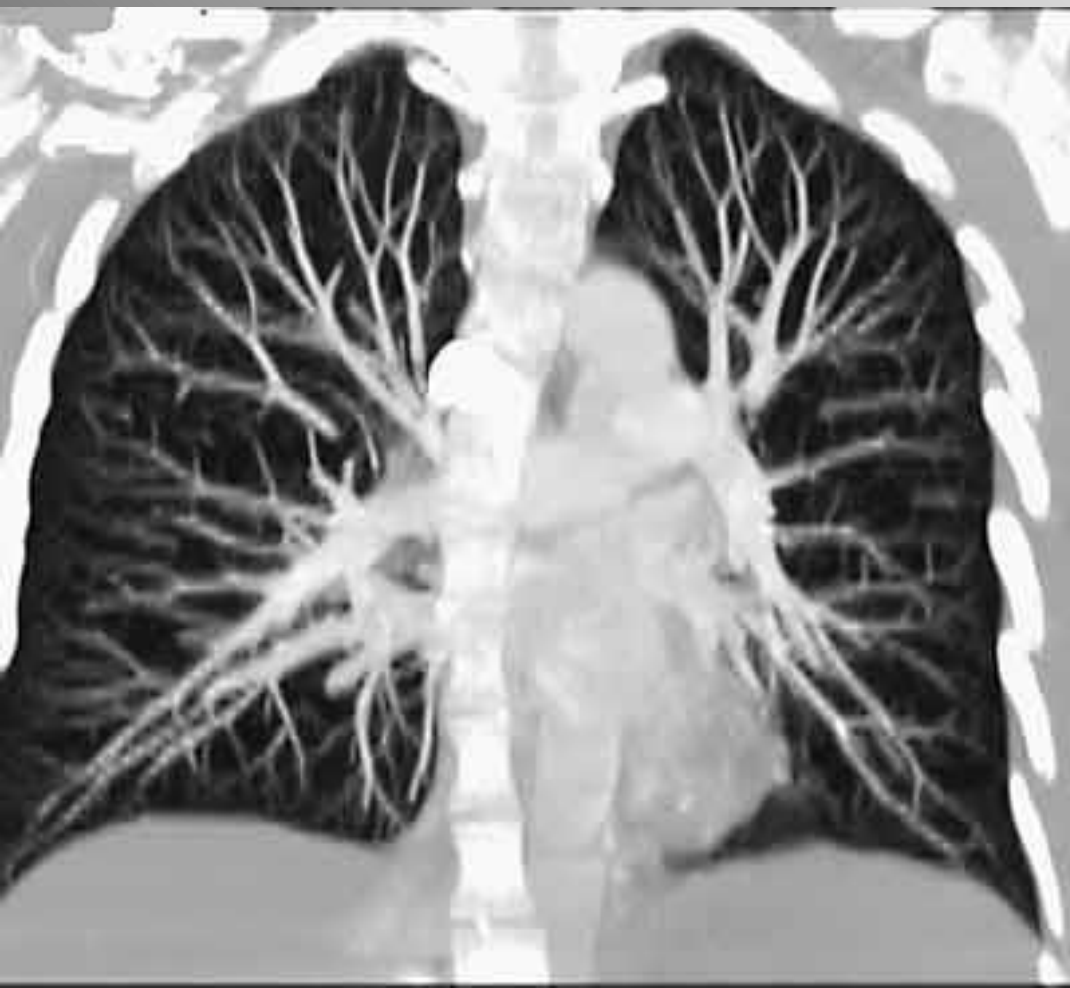C Lateral View

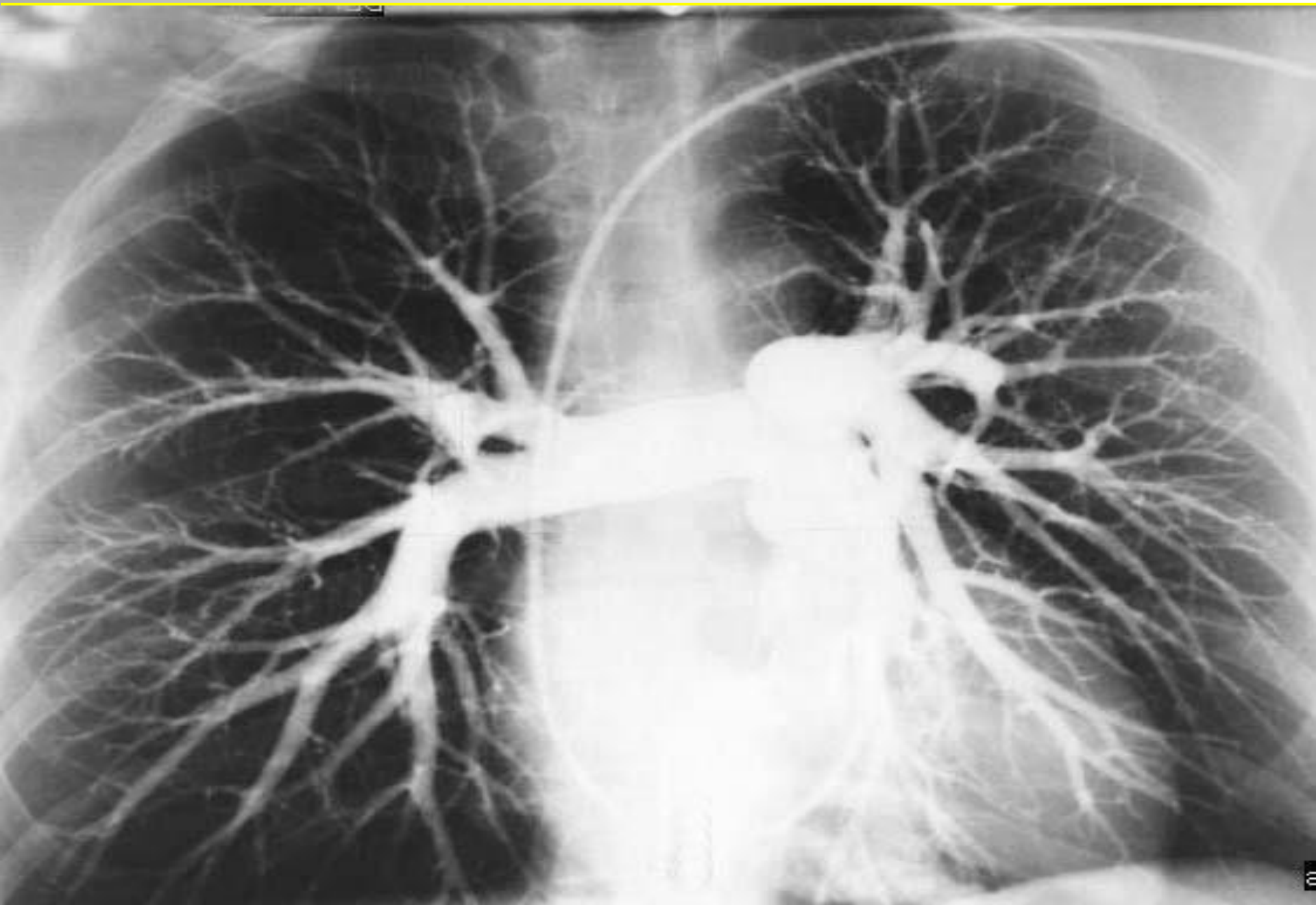
VISCERA OF THORAX (ANTERIOR VIEW)







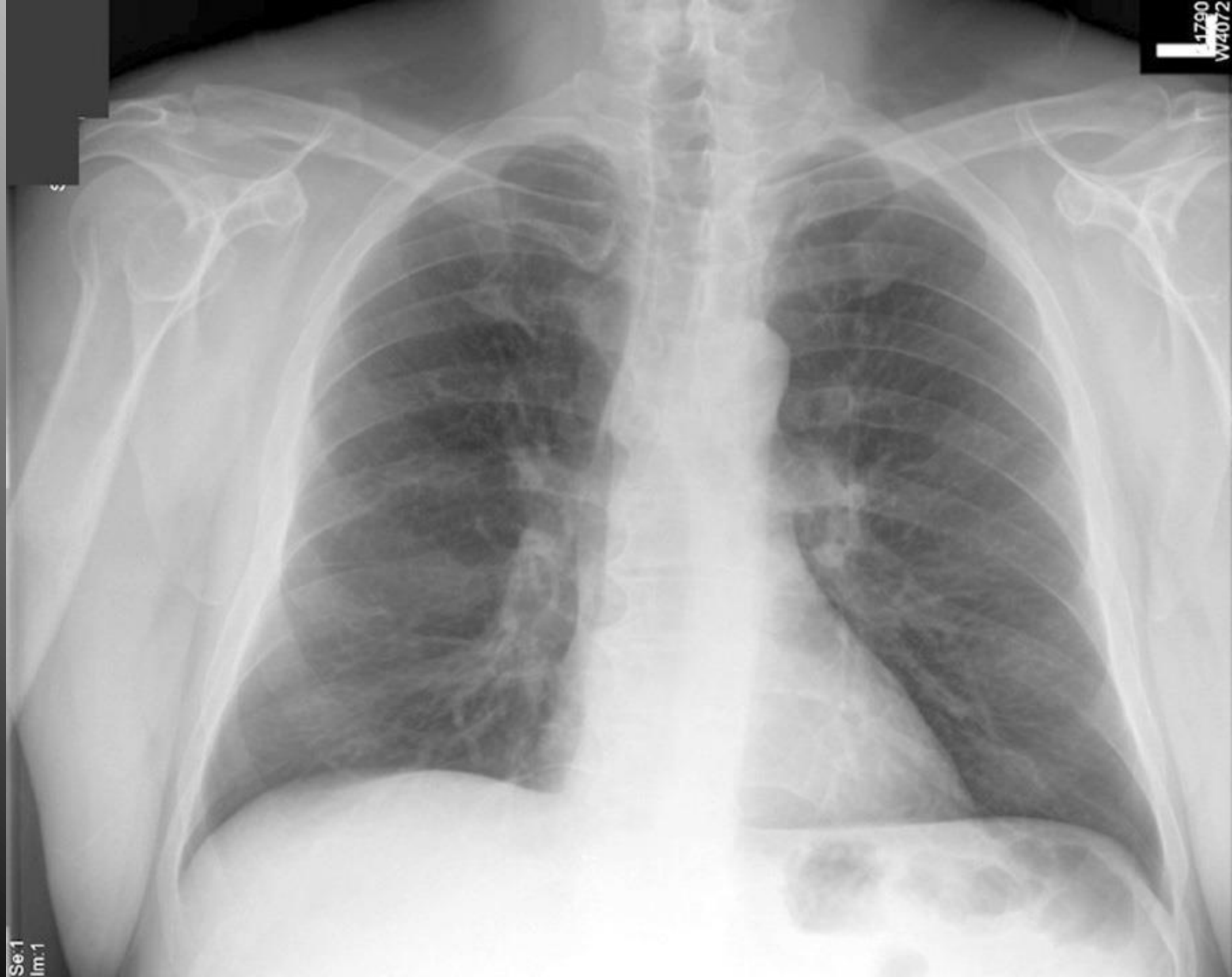



Densities on X-ray

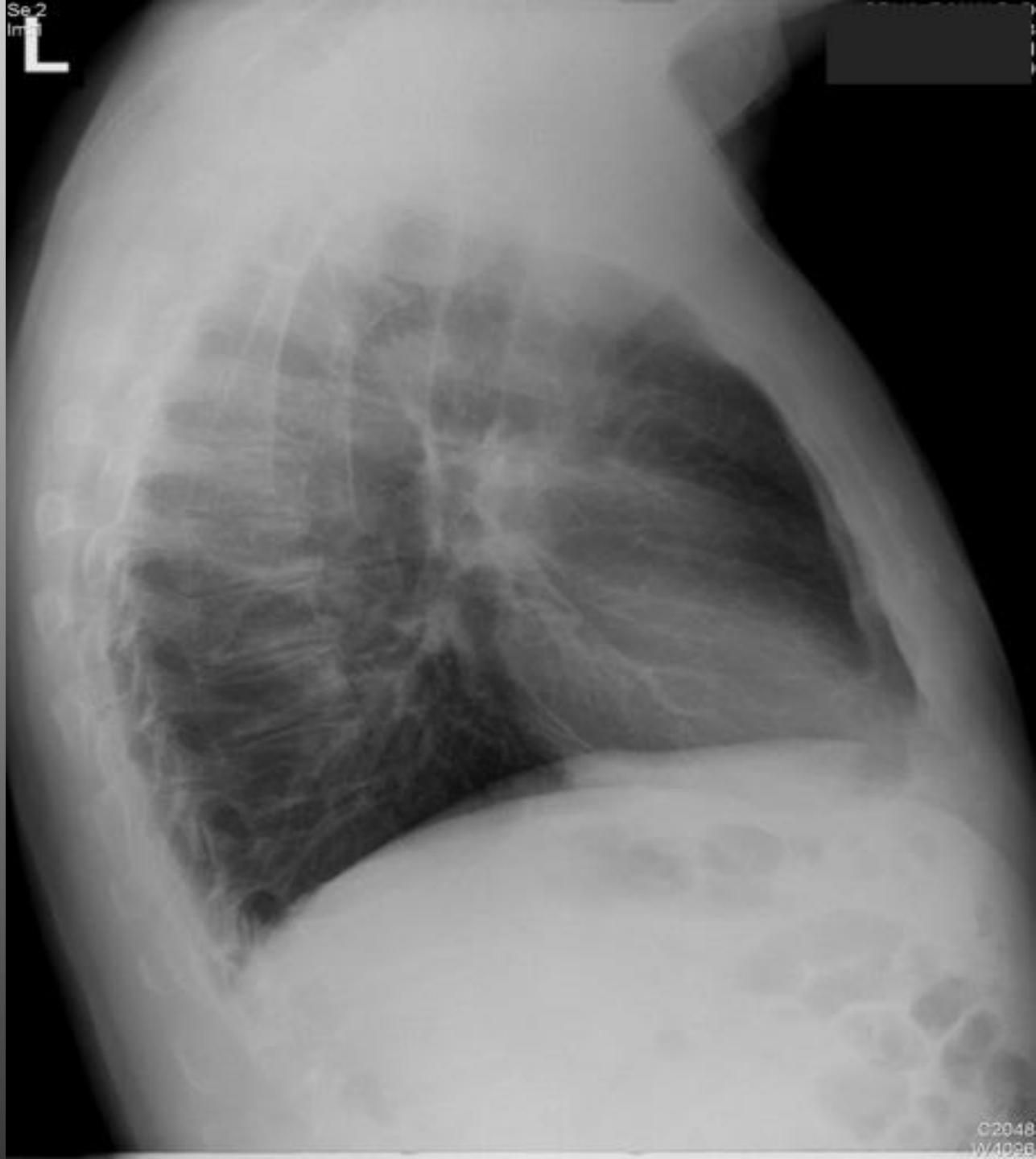- **Acid Fast Tuberculosis**
- **A.F.T.B.**
 - **A – Air**
 - **F – Fluid/Fat**
 - **T – Tissue**
 - **B – Bone**
 - **(CALCIUM)**

Se:1
Im:1

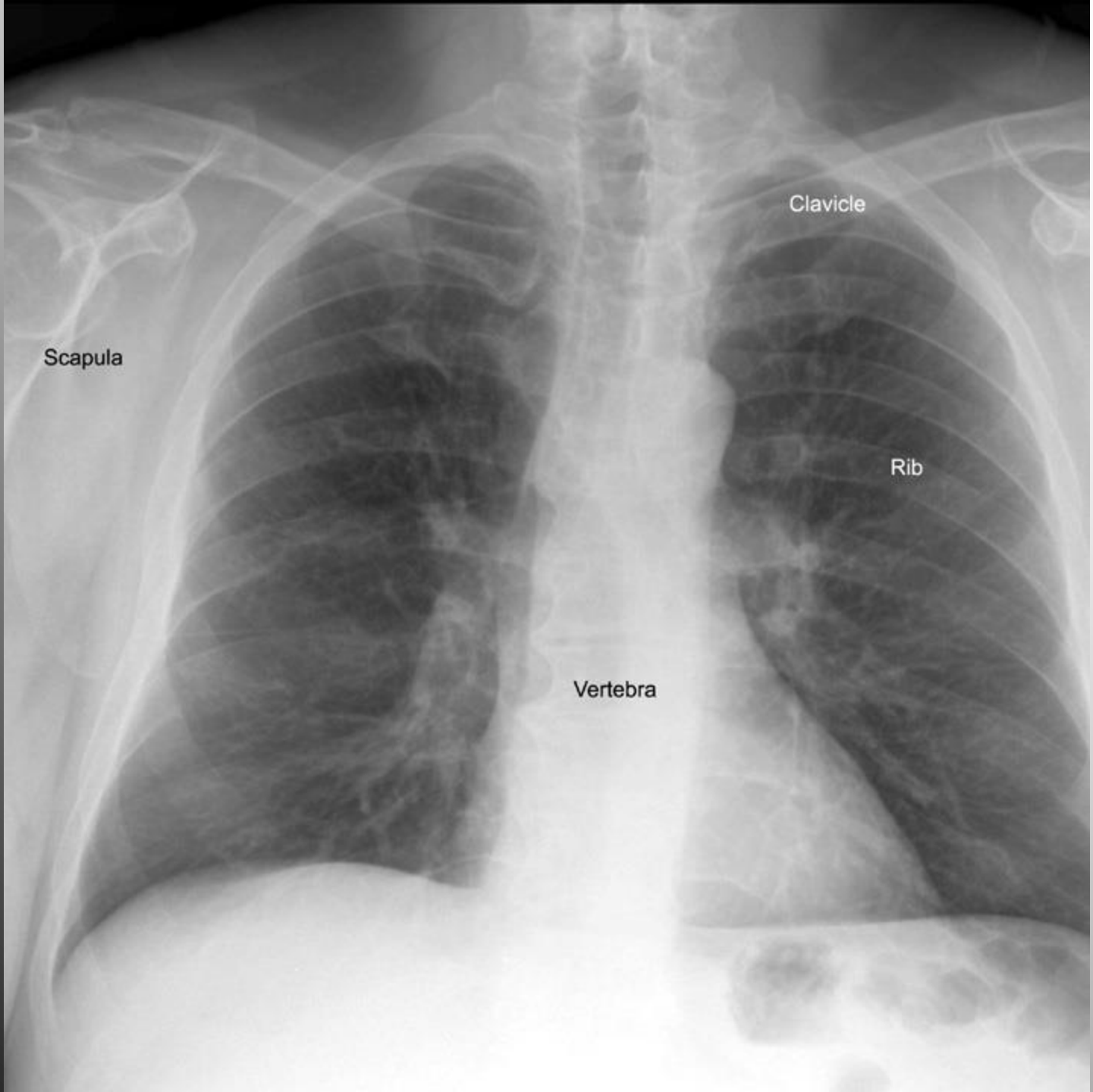


1790
W4072

Se. 2
img



C2048
W/4026

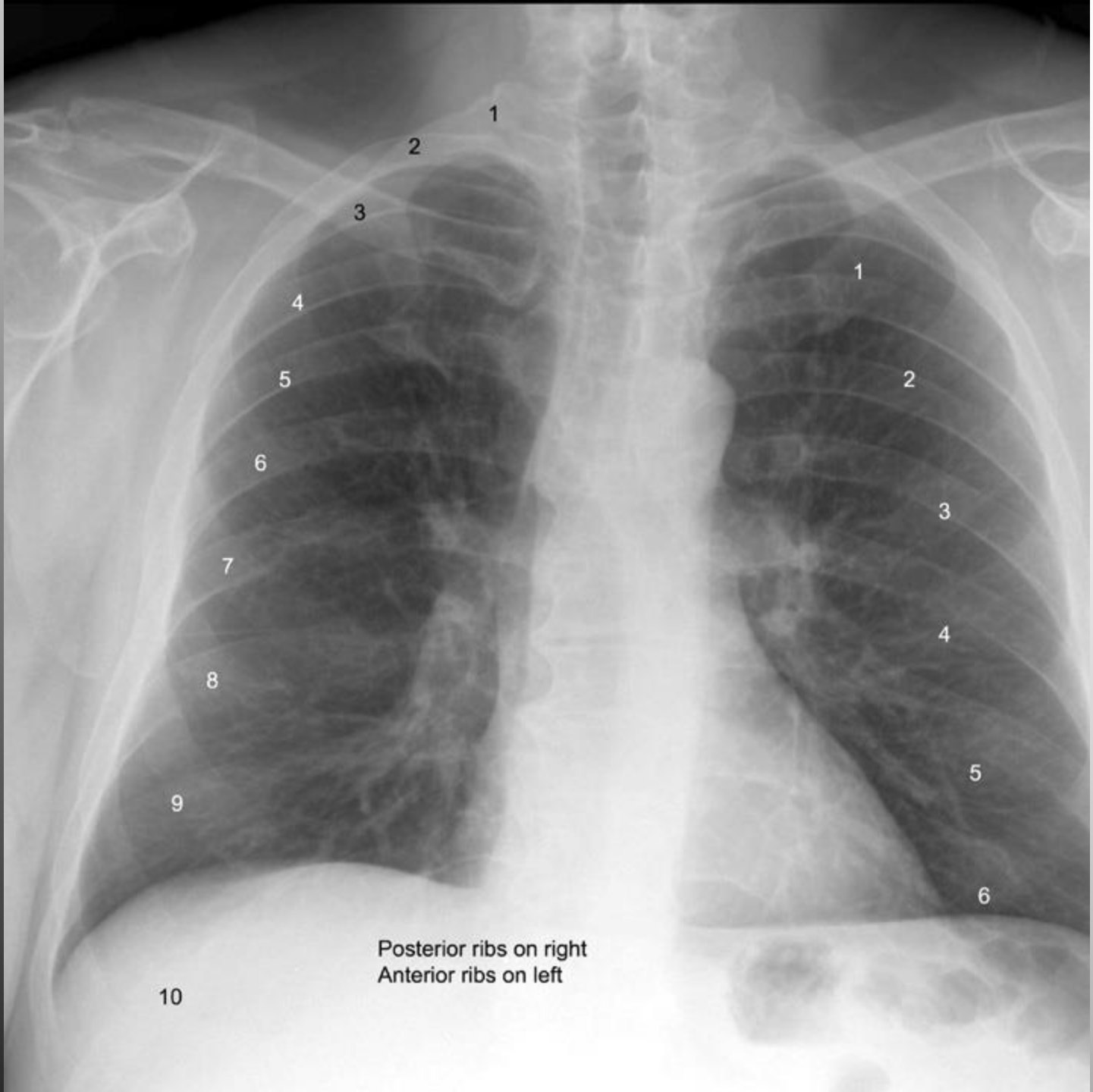


Scapula

Clavicle

Rib

Vertebra



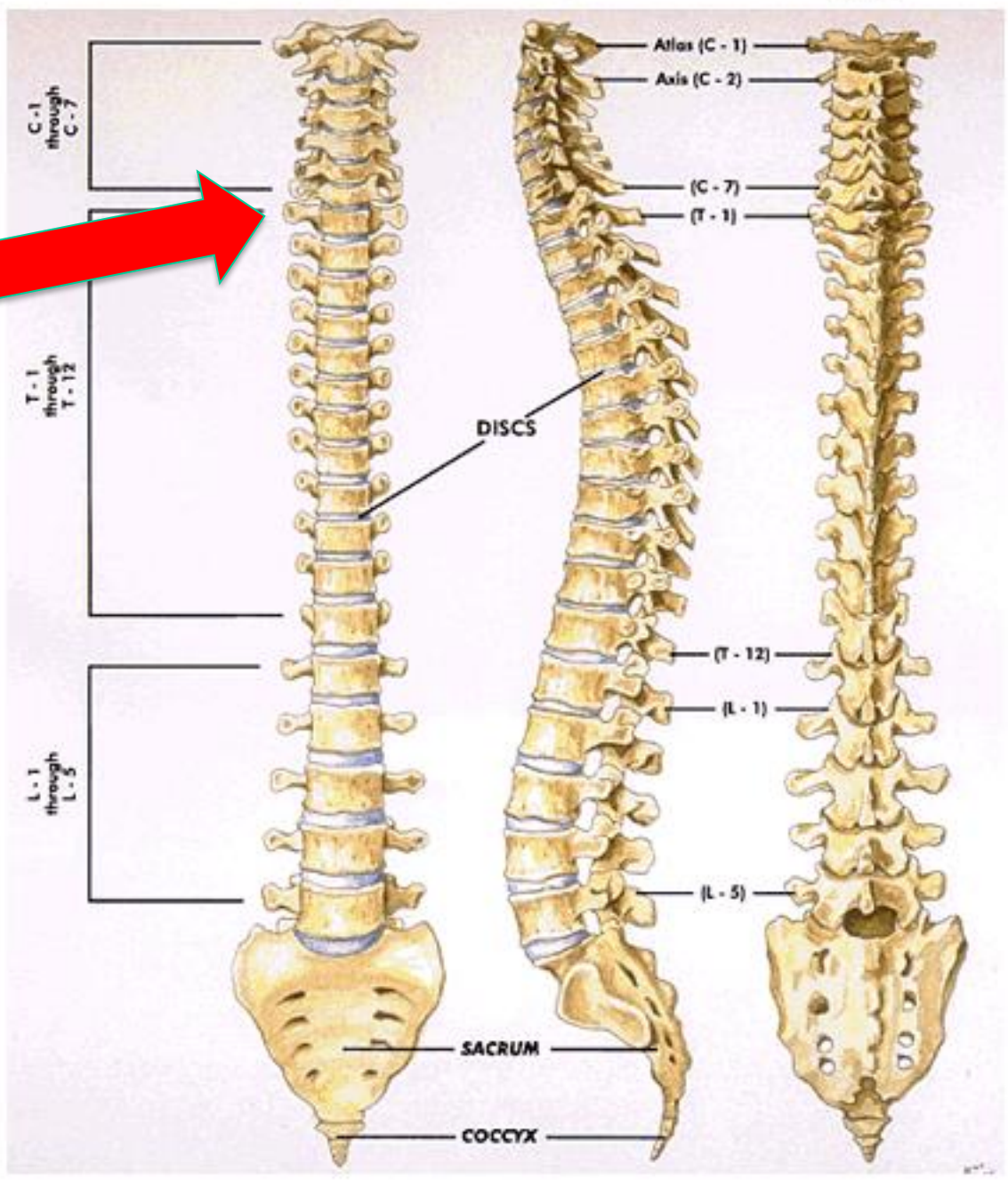
Posterior ribs on right
Anterior ribs on left

10

Anterior view

Left lateral view

Posterior view



C-1
through
C-7

T-1
through
T-12

L-1
through
L-5

Atlas (C-1)

Axis (C-2)

(C-7)

(T-1)

DISCS

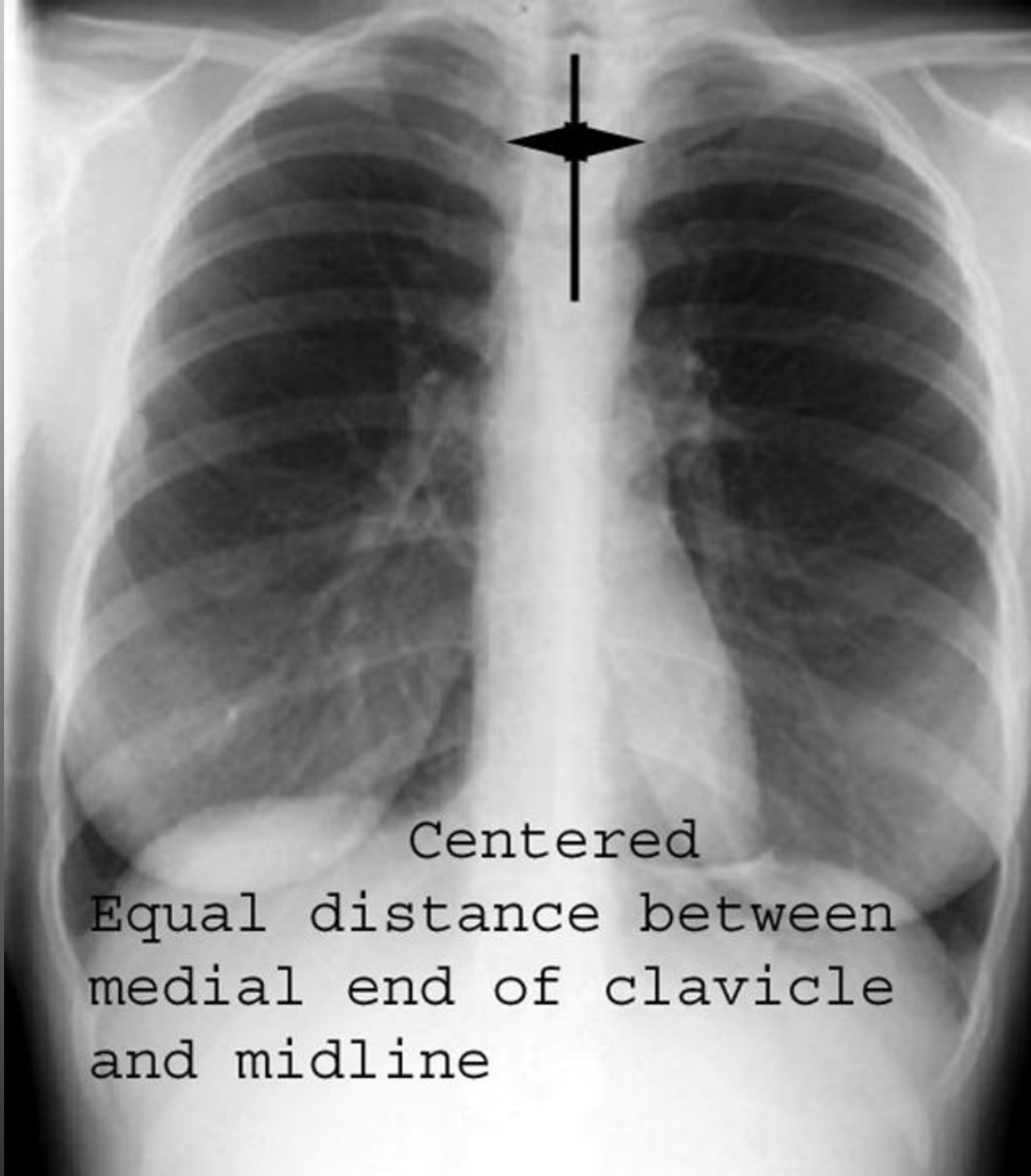
(T-12)

(L-1)

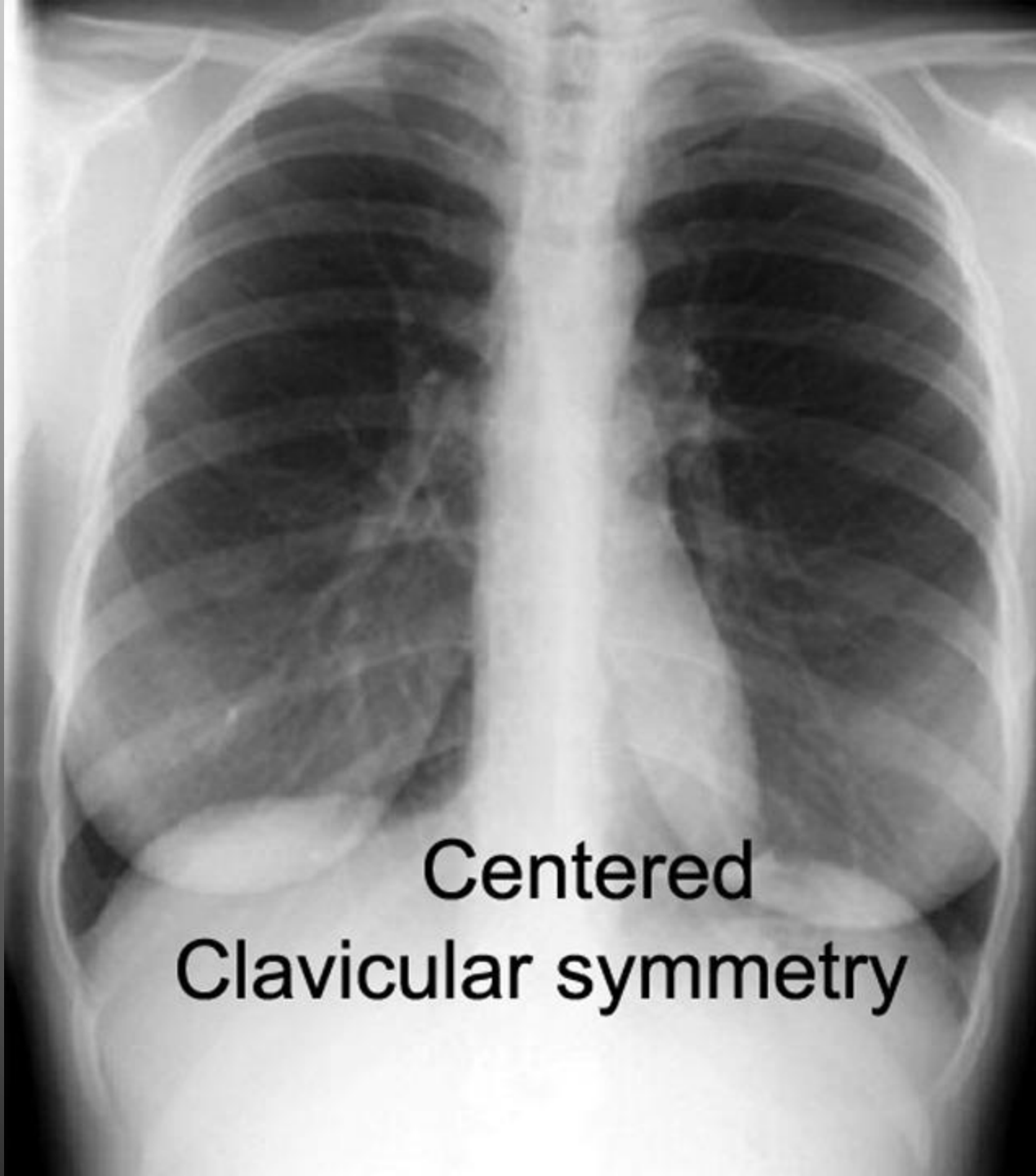
(L-5)

SACRUM

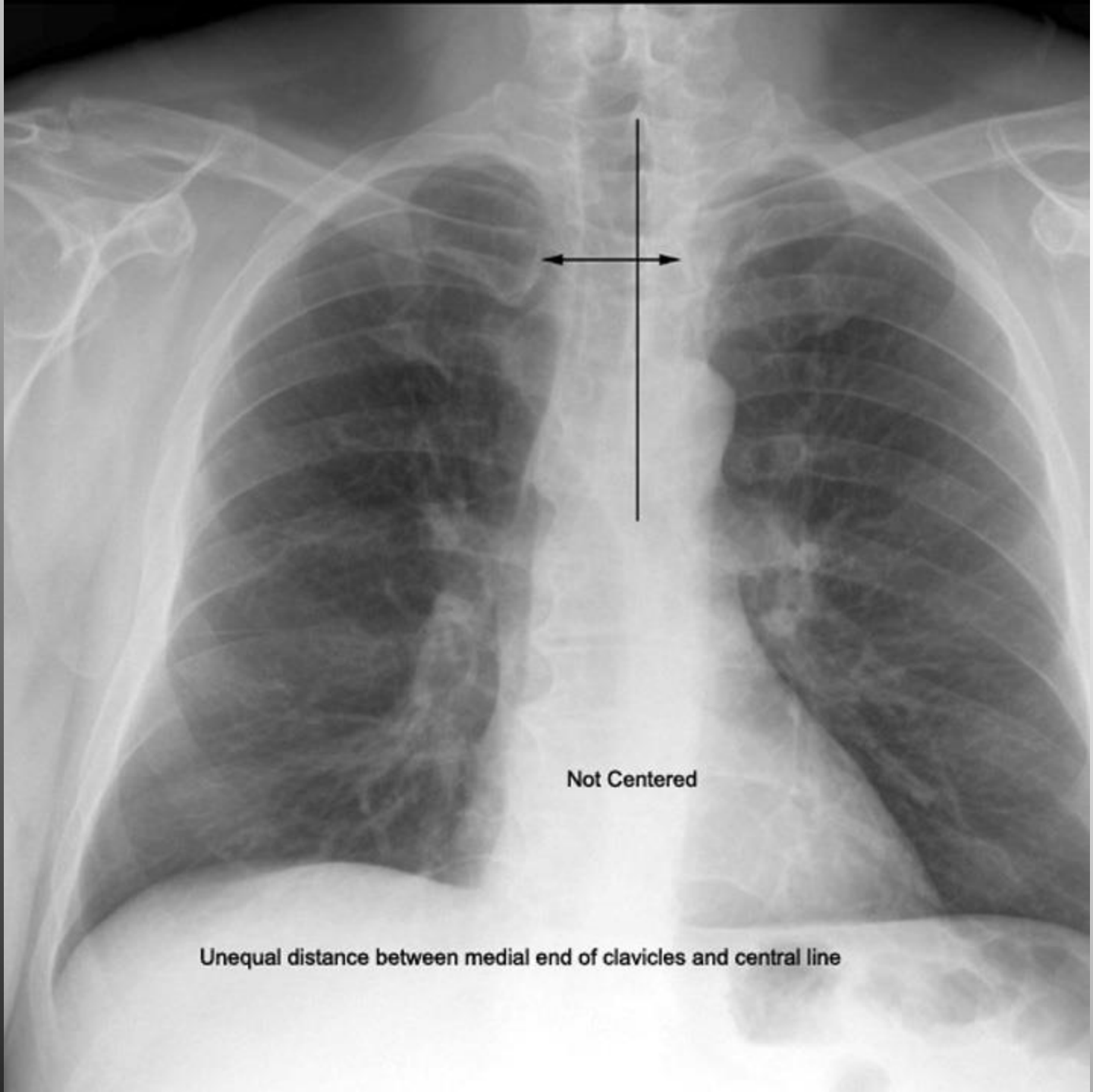
COCCYX



Centered
Equal distance between
medial end of clavicle
and midline

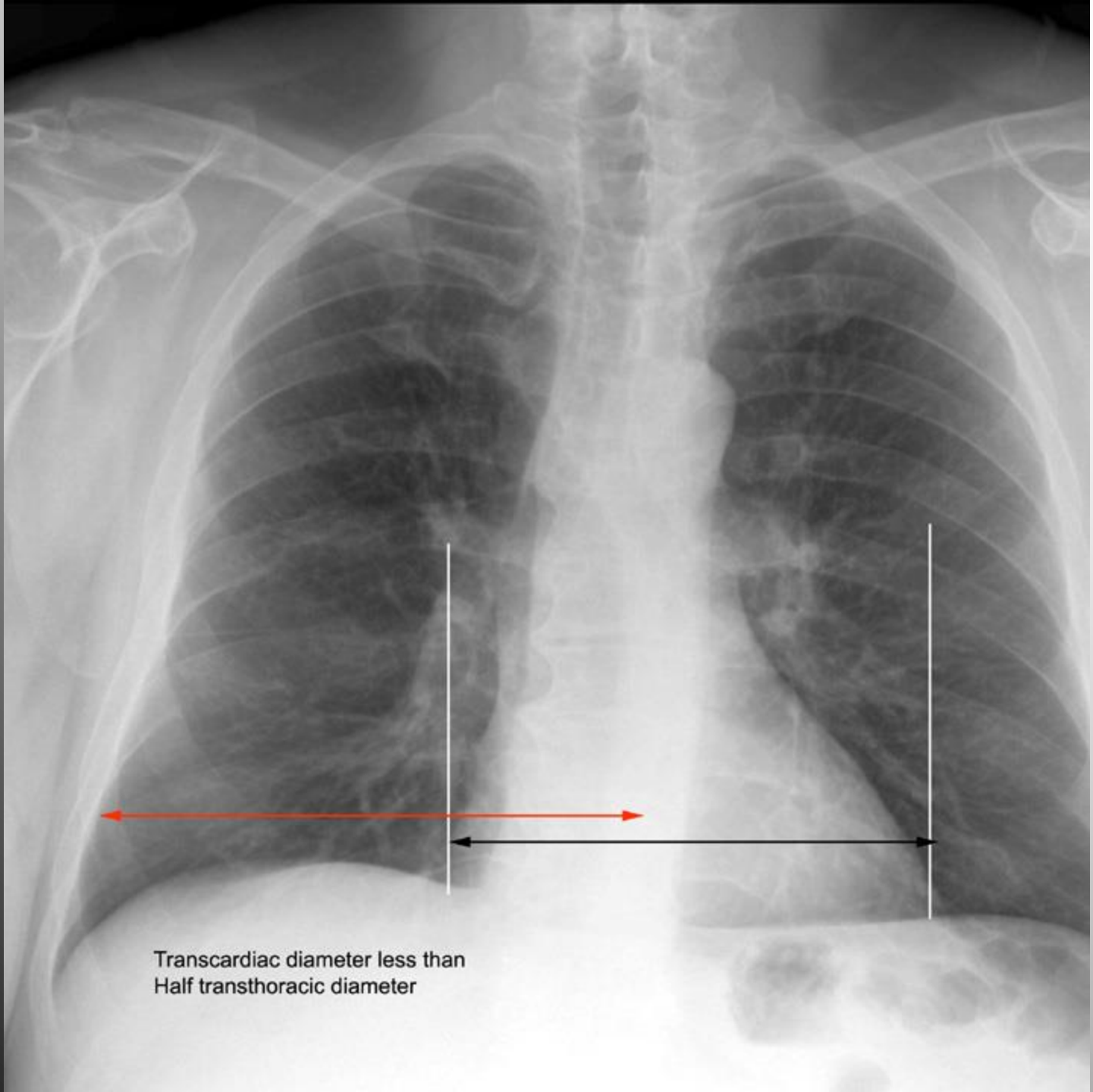


**Centered
Clavicular symmetry**

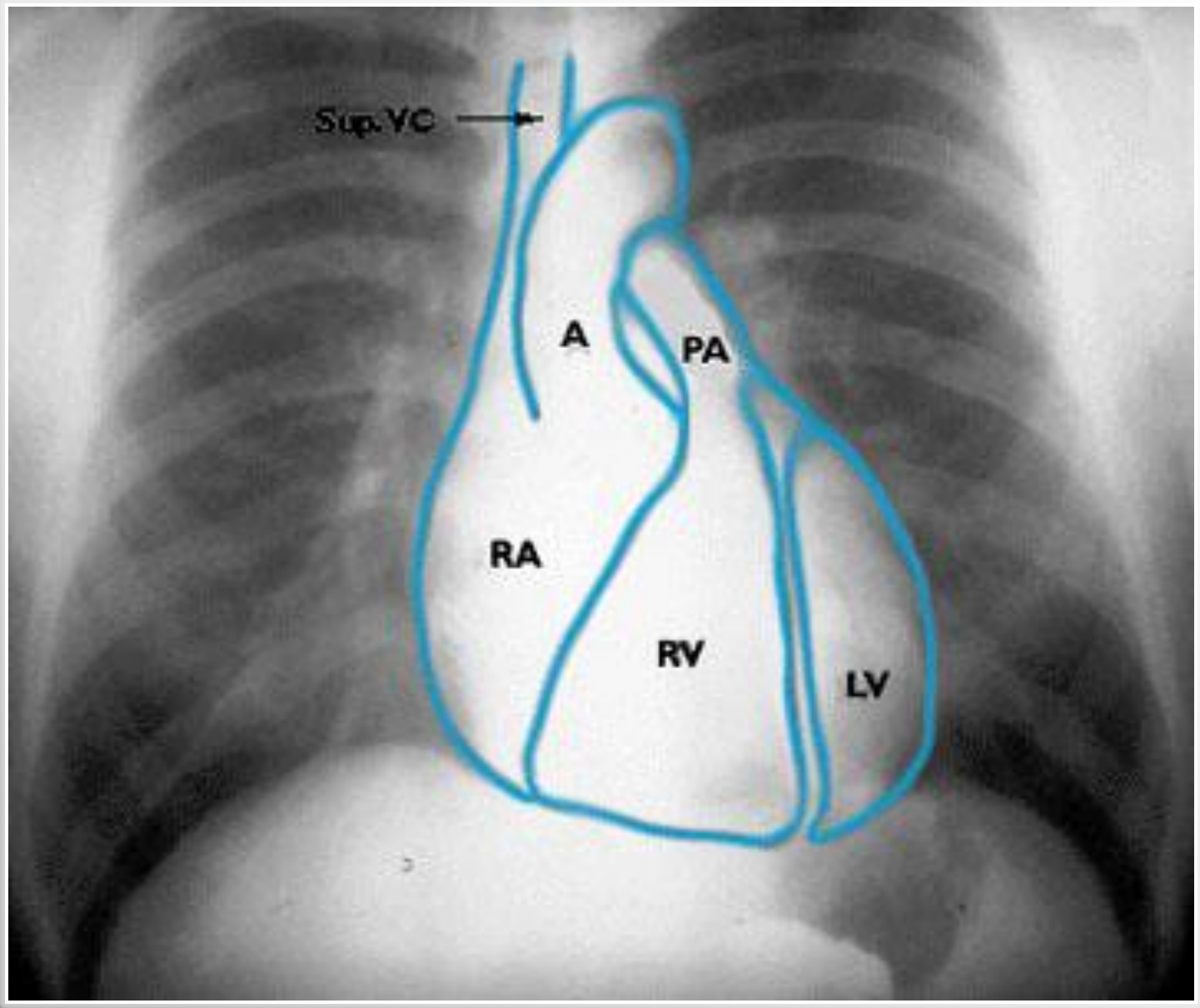


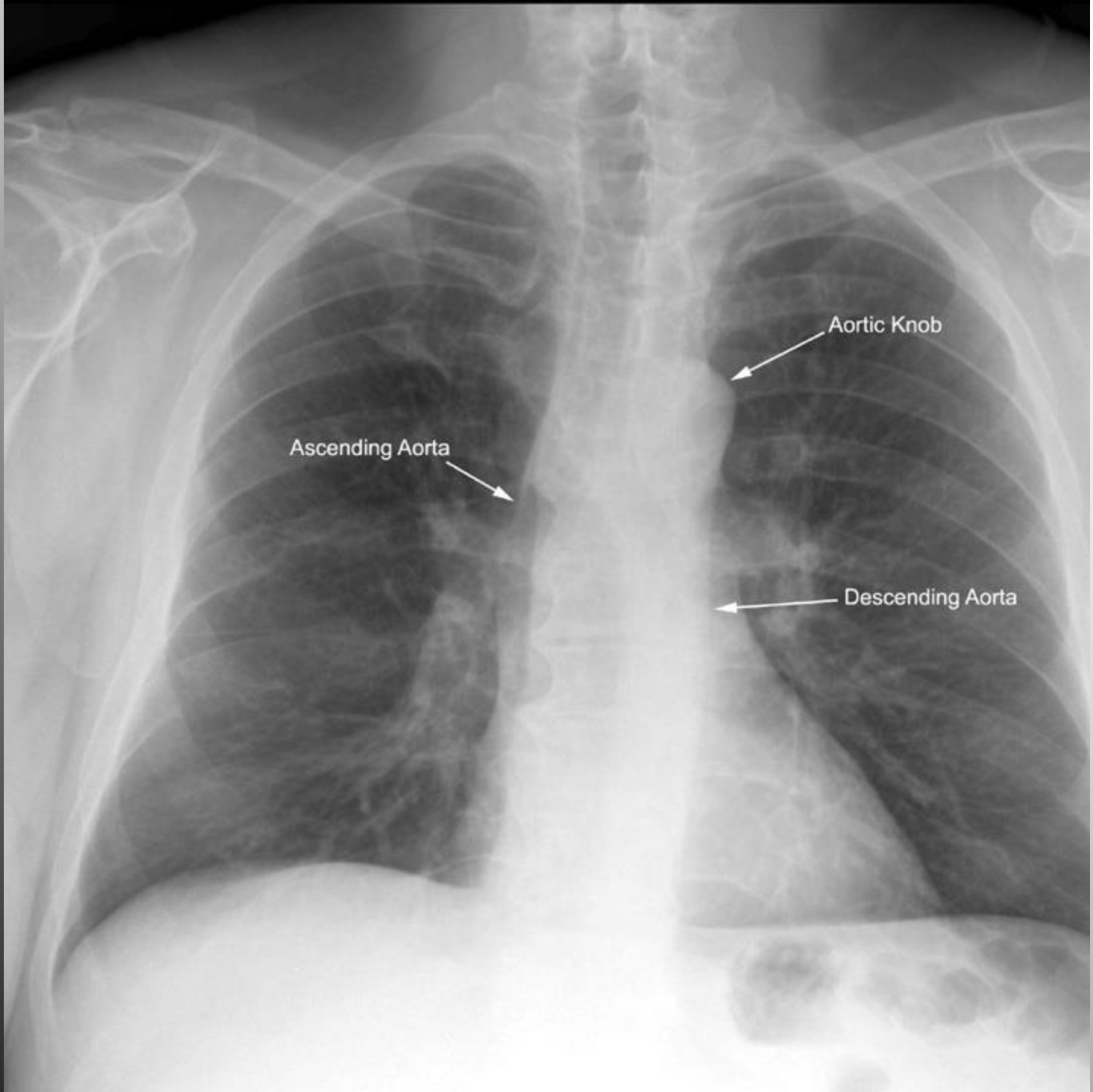
Not Centered

Unequal distance between medial end of clavicles and central line



Transcardiac diameter less than
Half transthoracic diameter

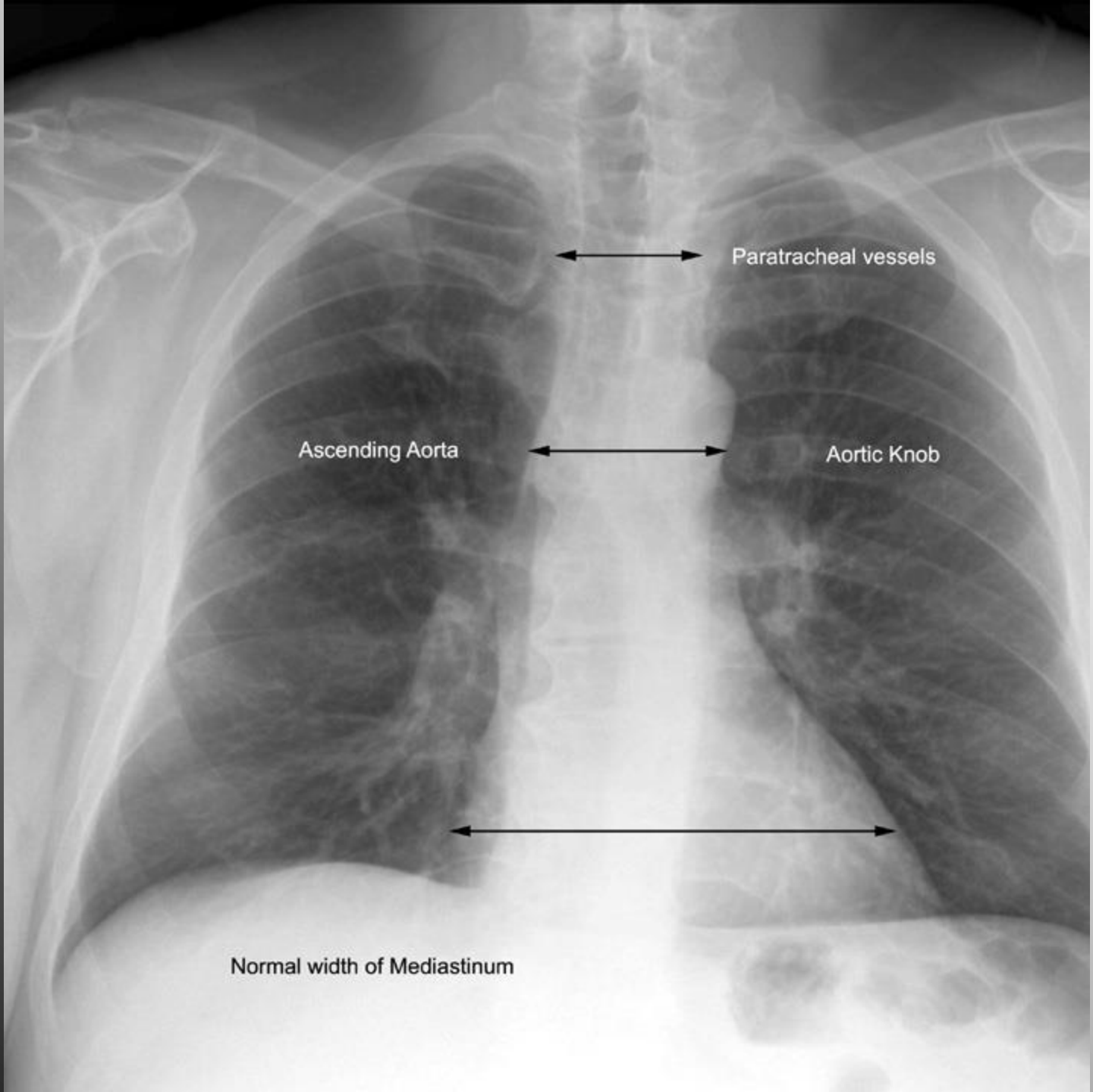




Ascending Aorta

Aortic Knob

Descending Aorta

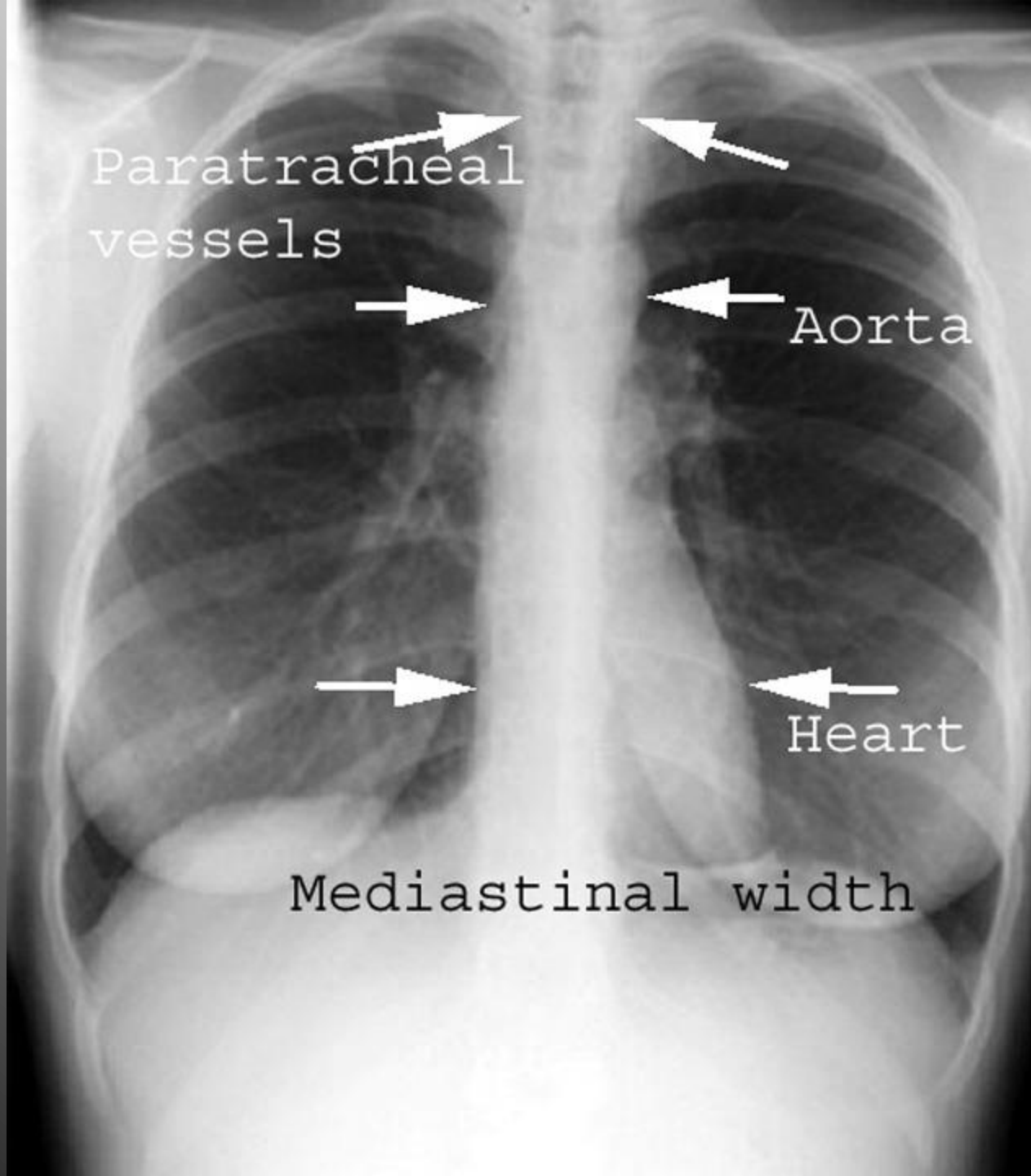


Paratracheal vessels

Ascending Aorta

Aortic Knob

Normal width of Mediastinum

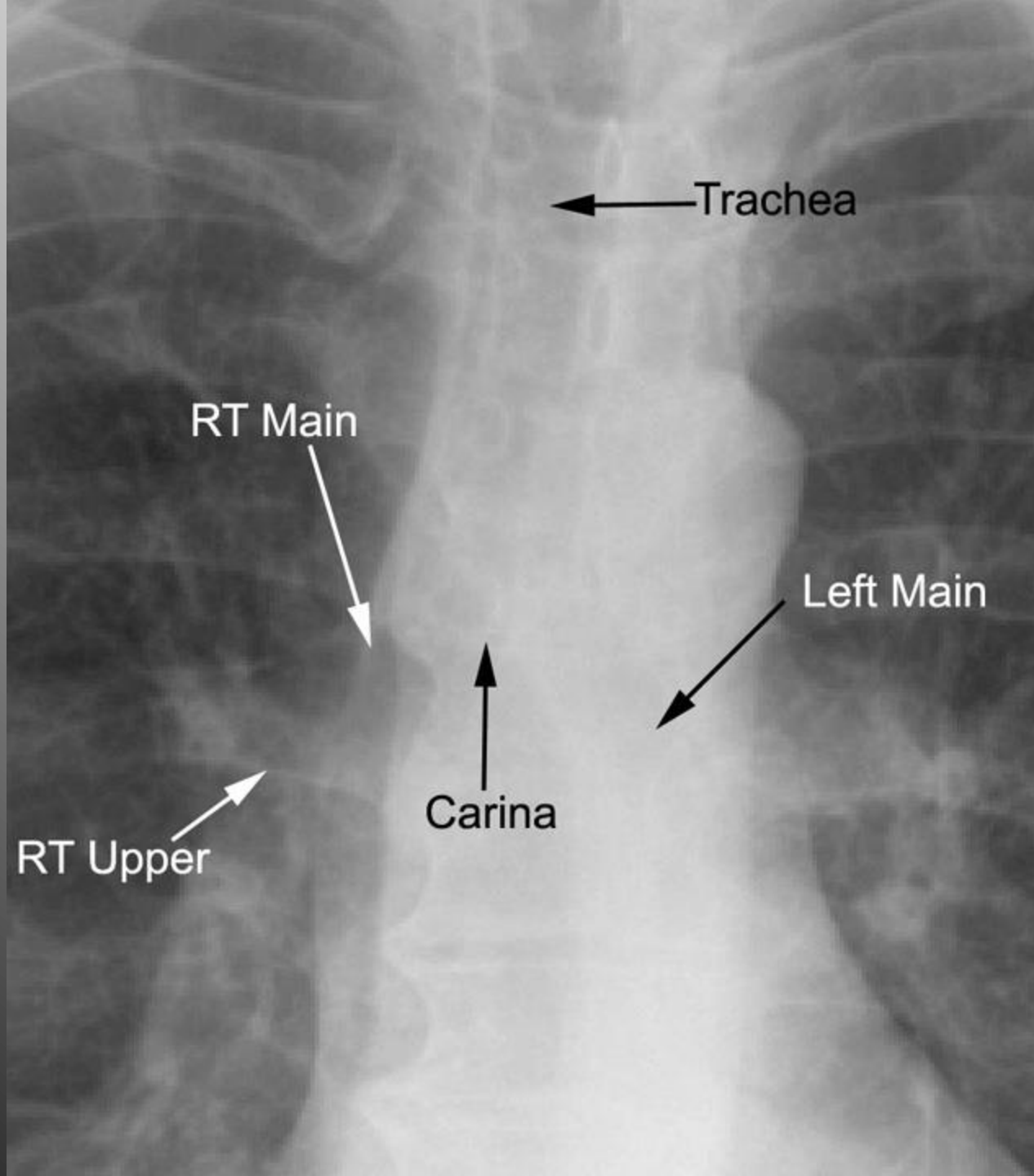


Paratracheal
vessels

Aorta

Heart

Mediastinal width



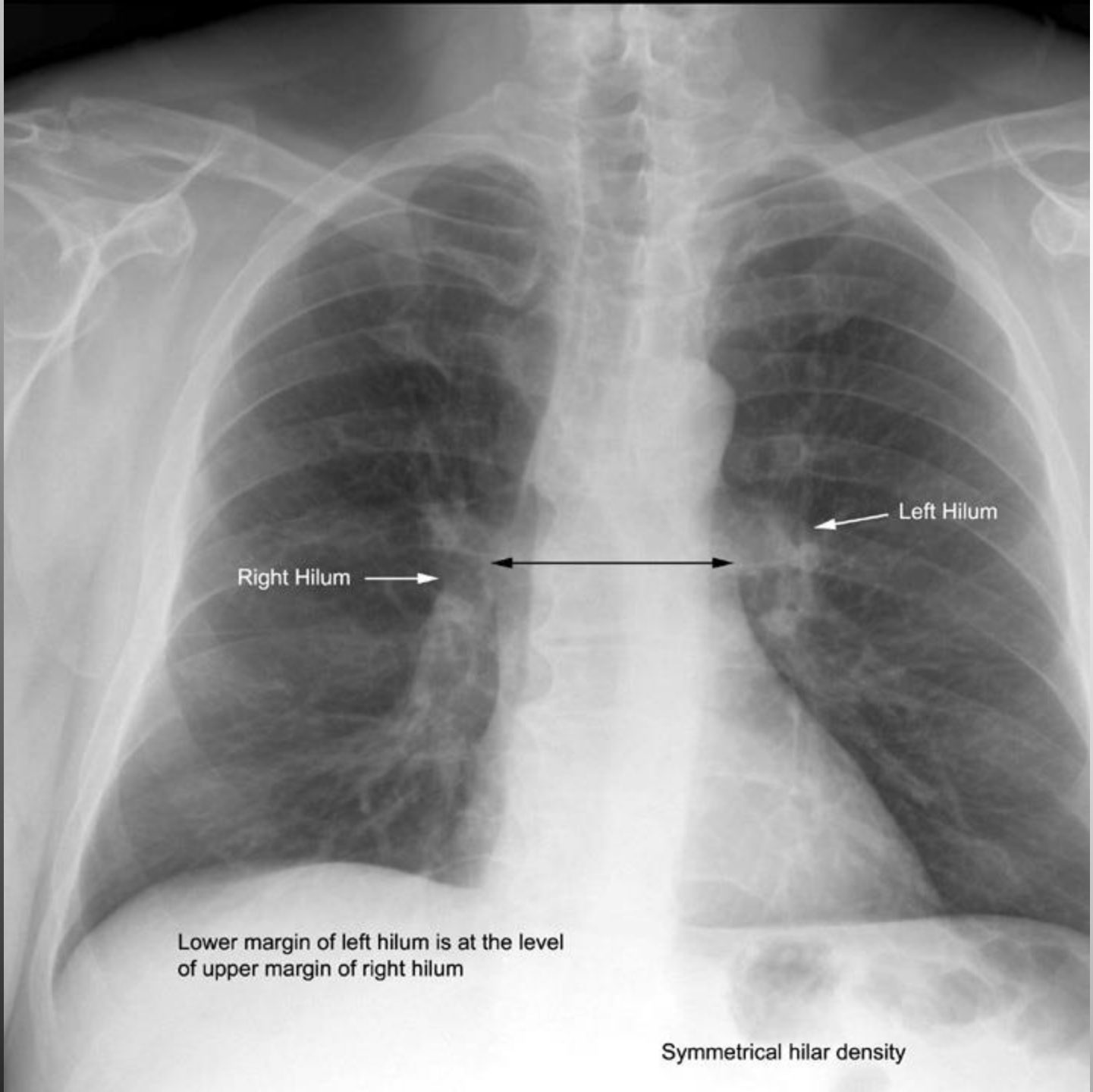
← Trachea

RT Main

Left Main

↑ Carina

RT Upper

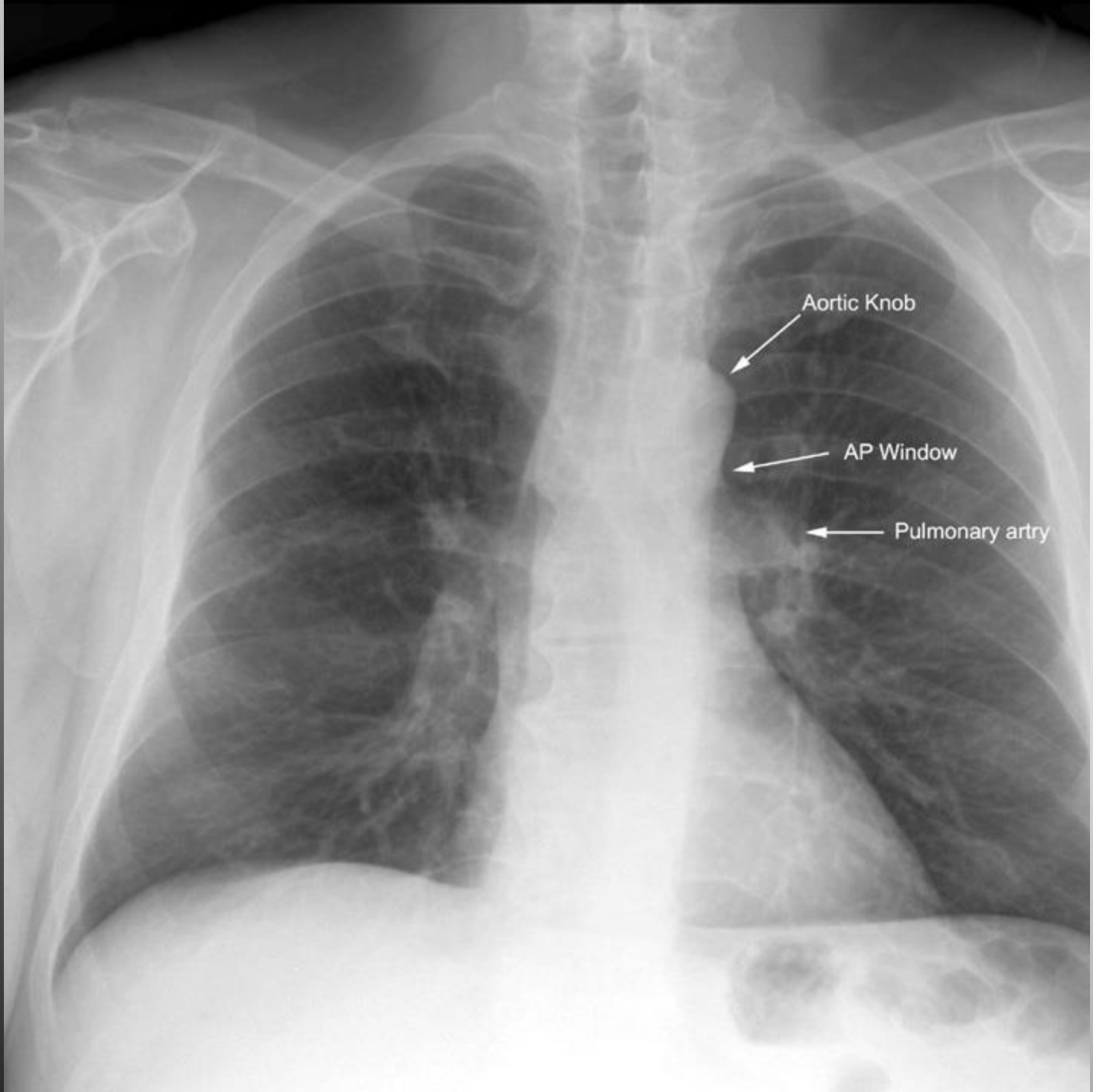


Right Hilum →

← Left Hilum

Lower margin of left hilum is at the level of upper margin of right hilum

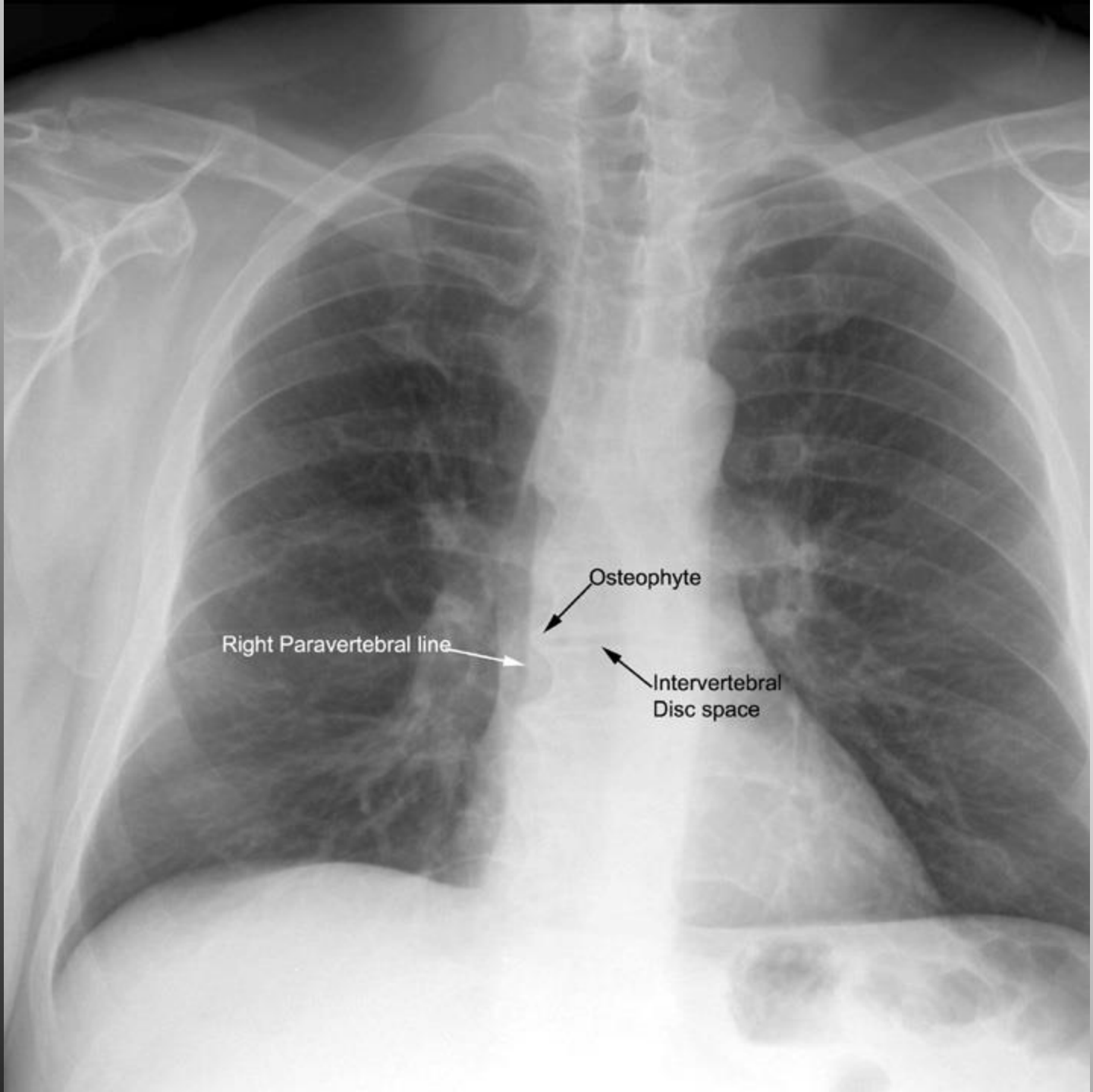
Symmetrical hilar density



Aortic Knob

AP Window

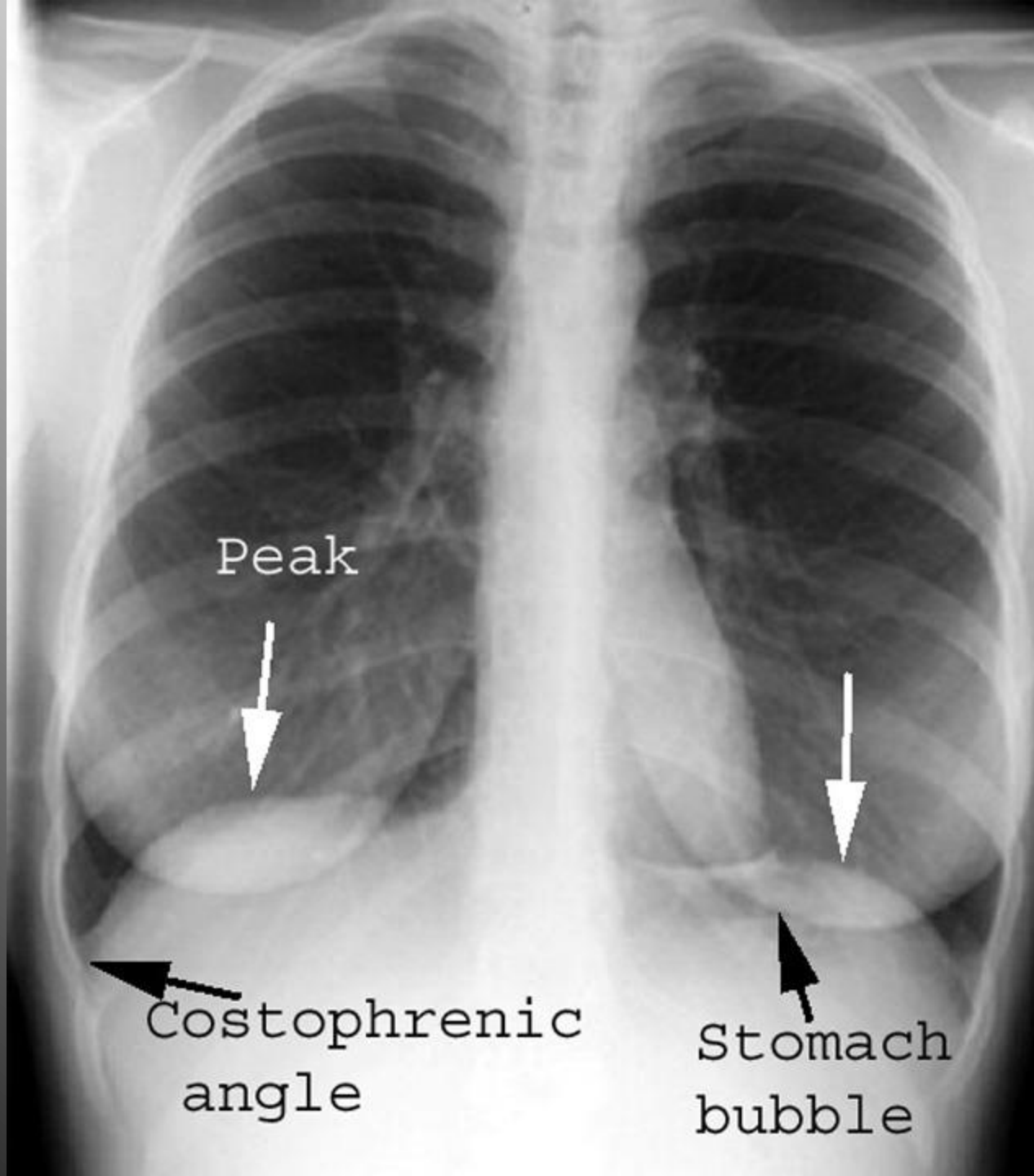
Pulmonary artery

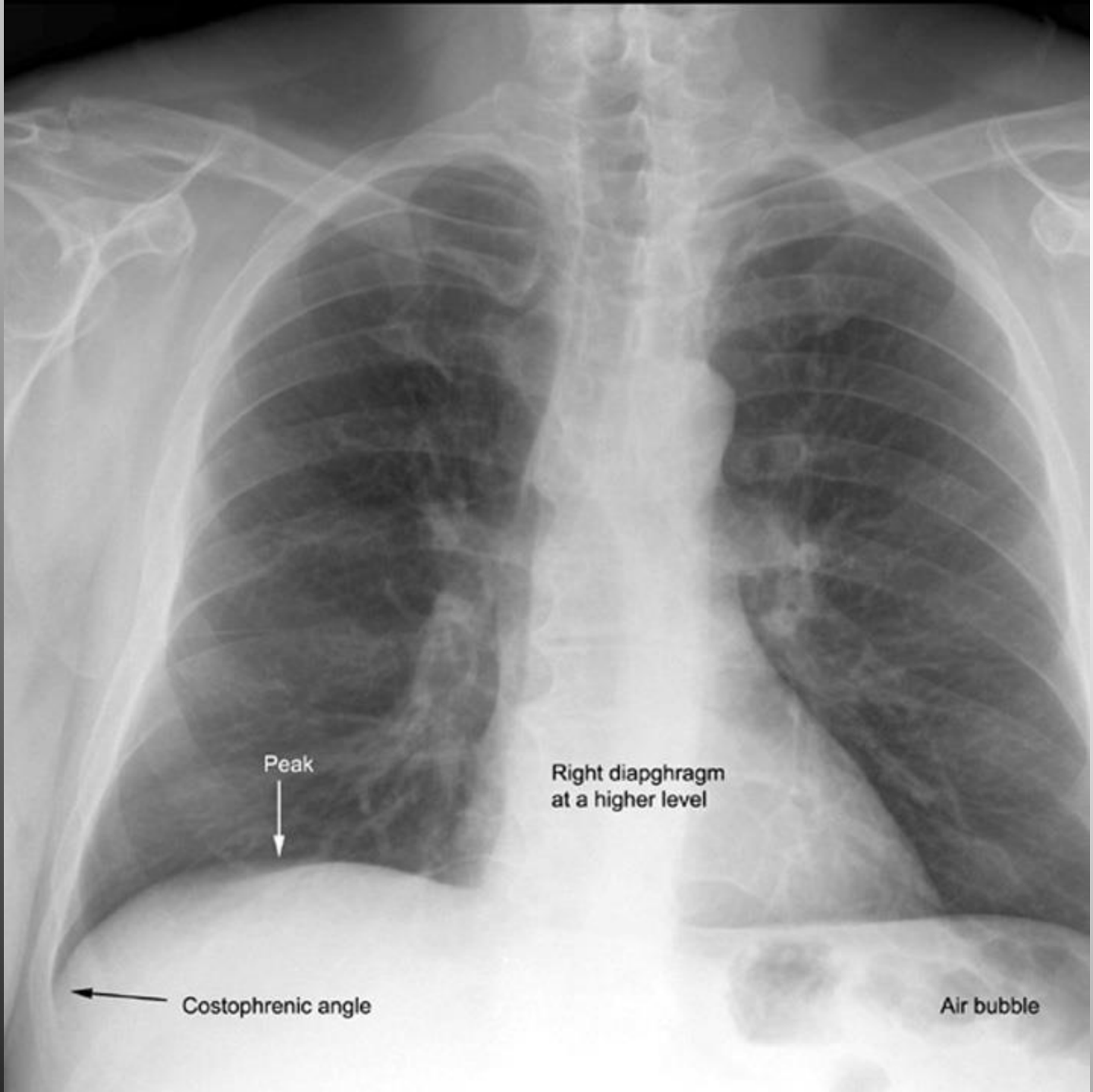


Right Paravertebral line

Osteophyte

Intervertebral
Disc space





Peak



Right diaphragm
at a higher level



Costophrenic angle

Air bubble

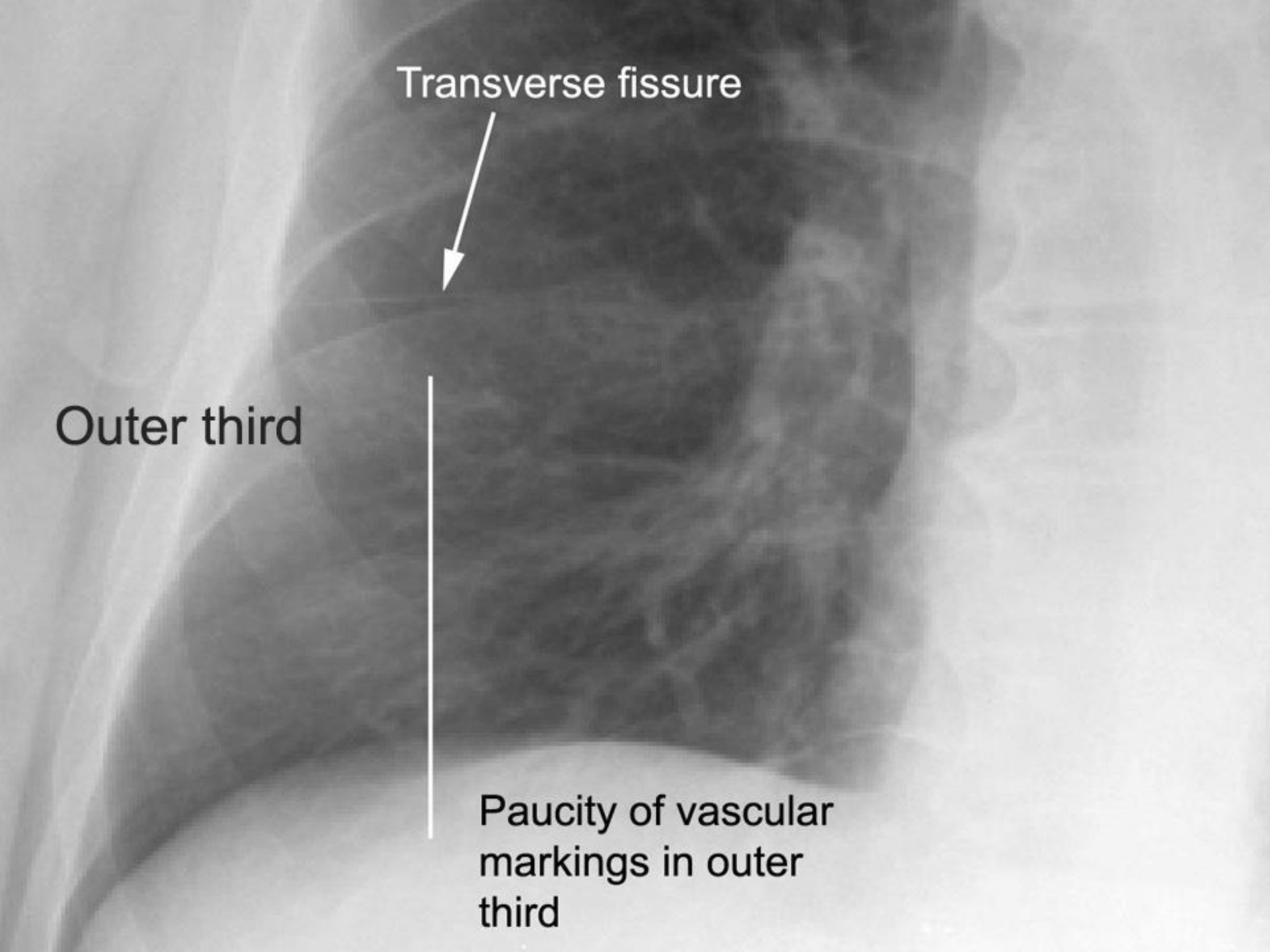
Transverse fissure

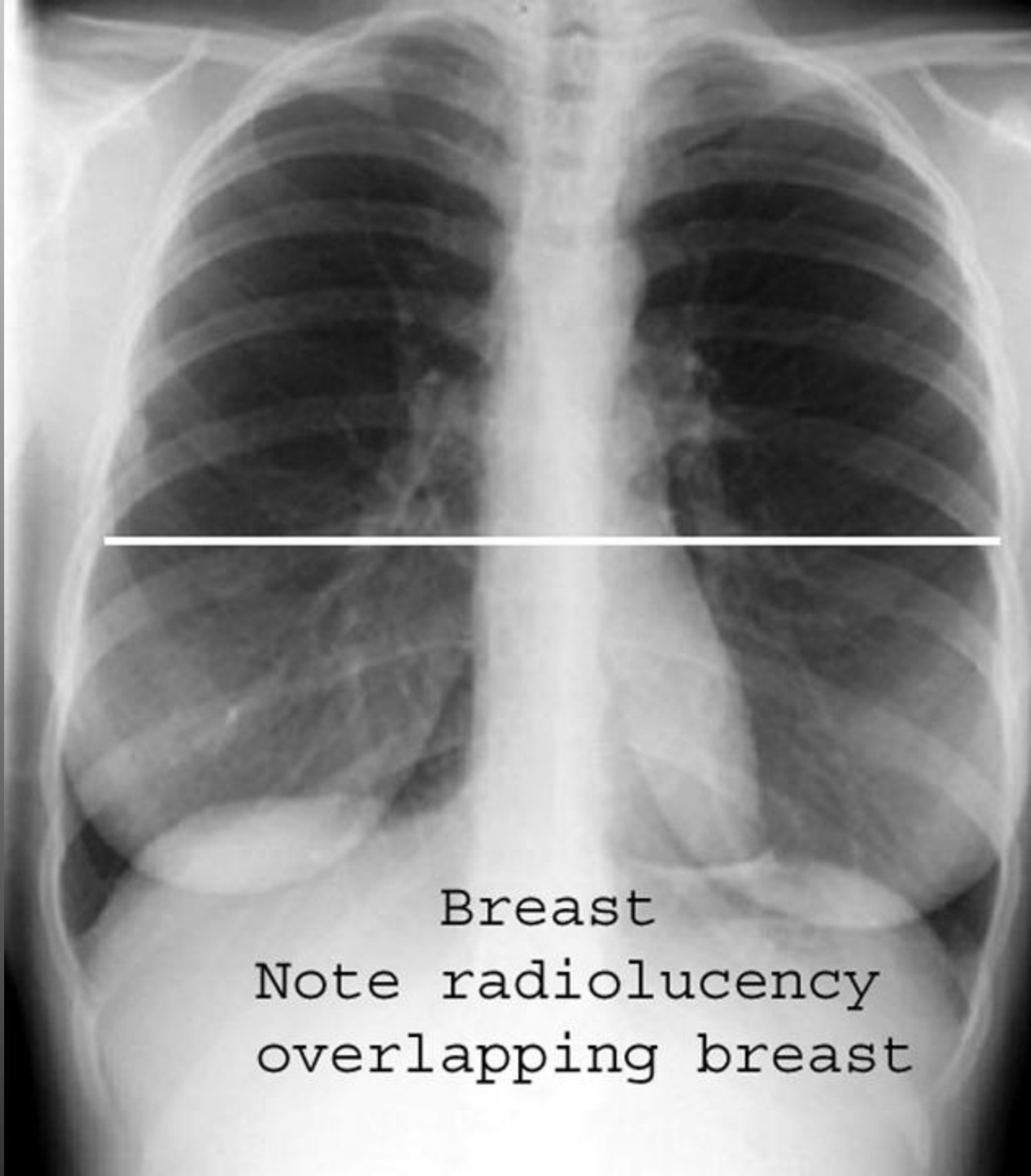


Outer third



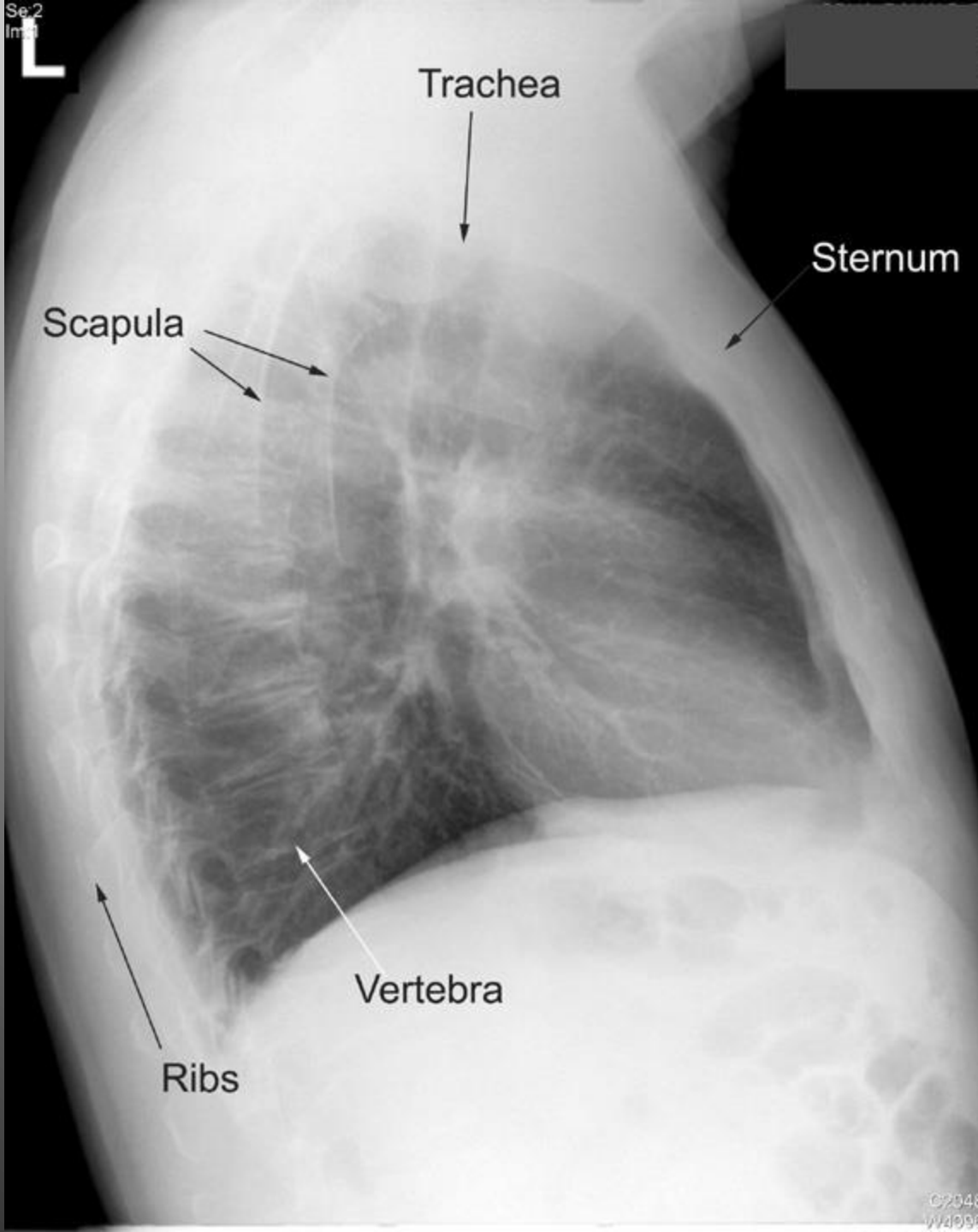
Paucity of vascular markings in outer third

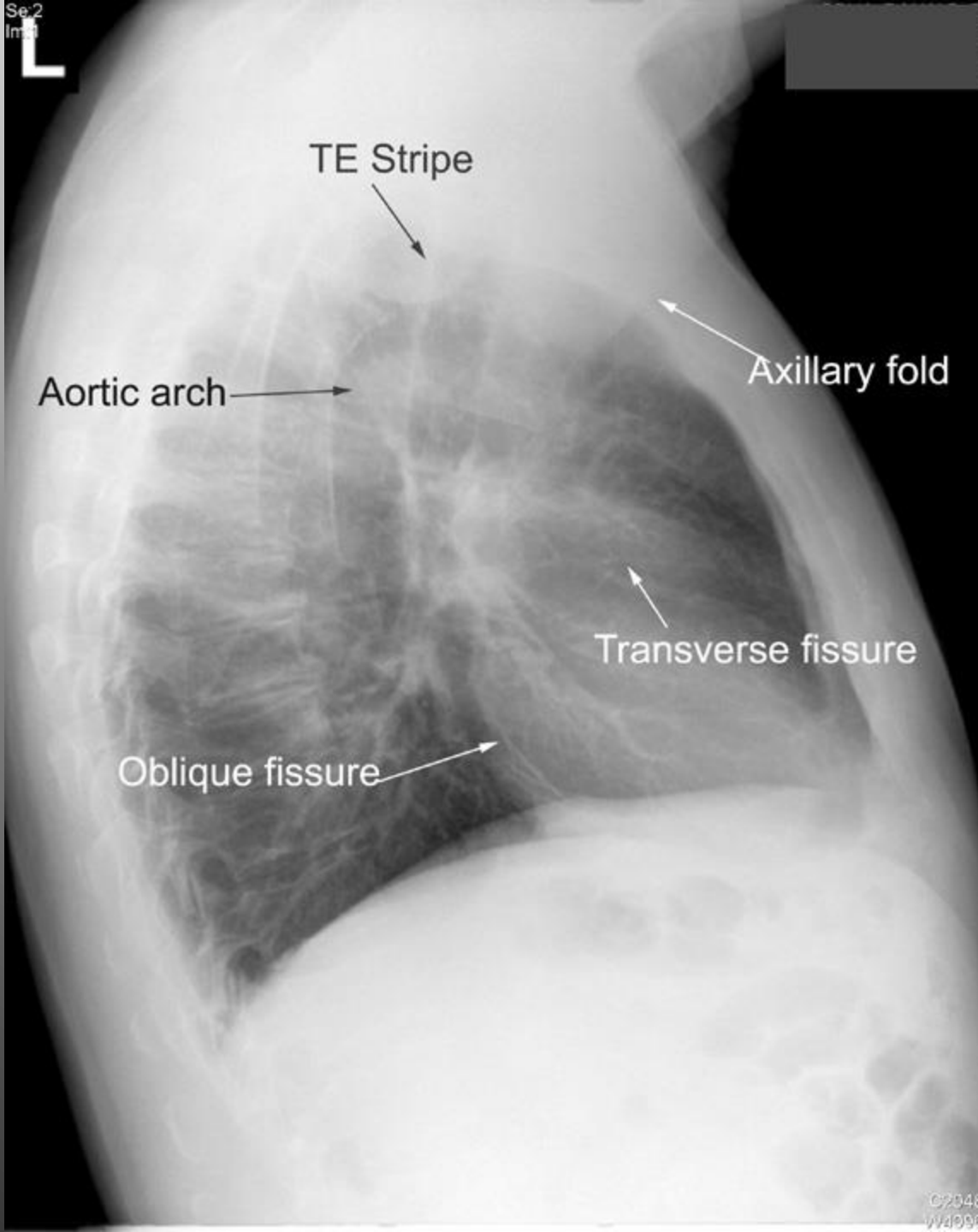


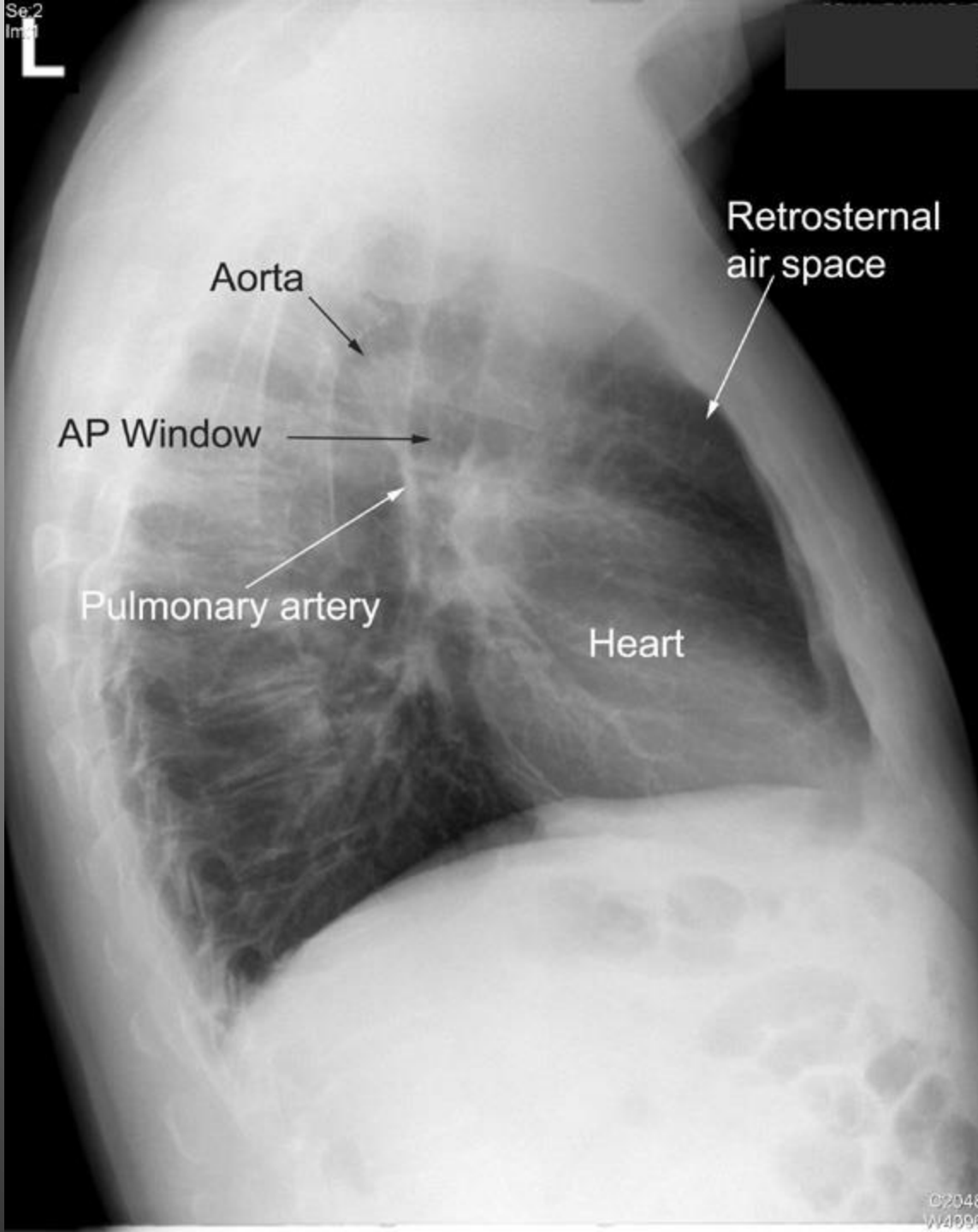


Breast
Note radiolucency
overlapping breast

Se. 2
Im 1







Aorta

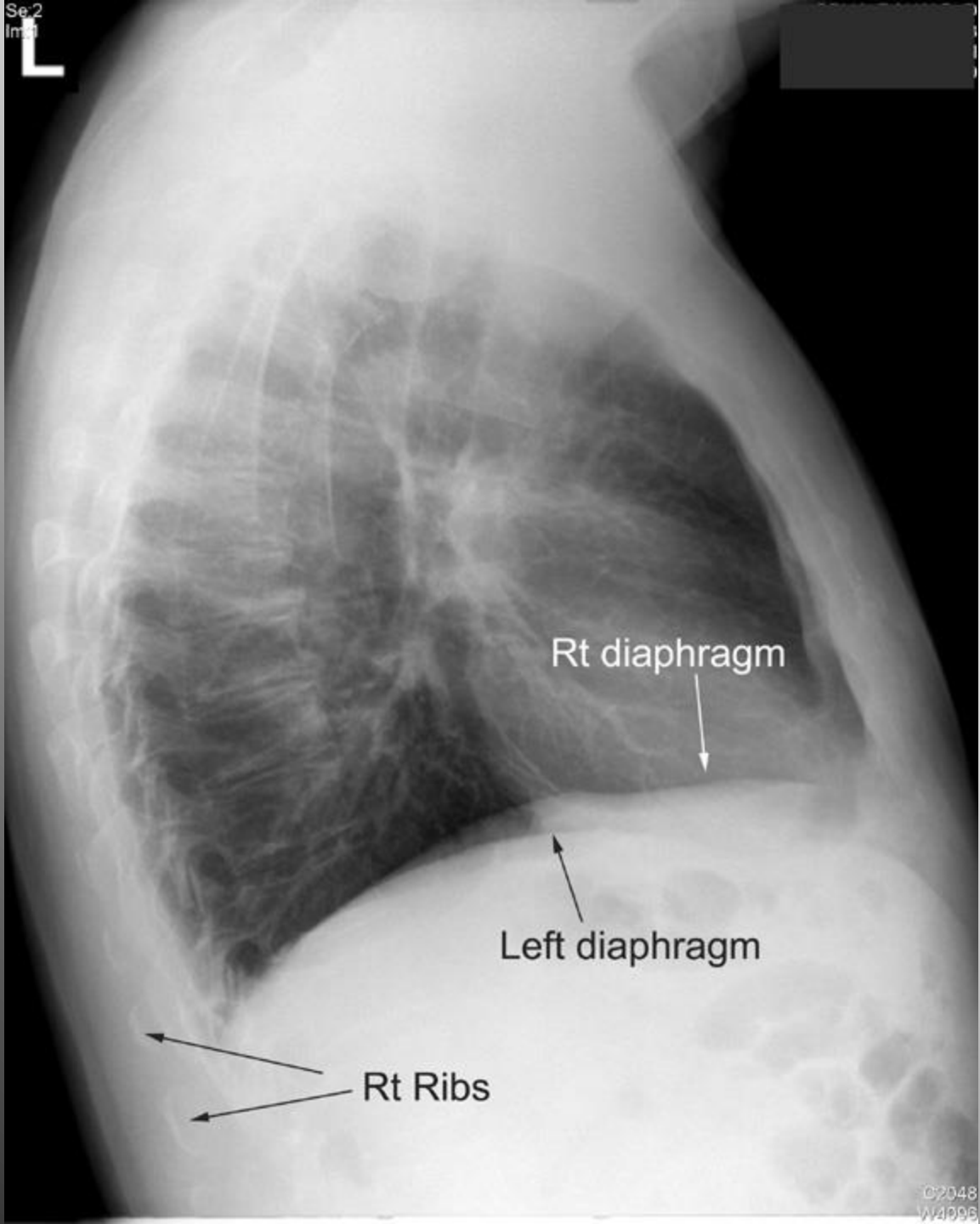
Retrosternal
air space

AP Window

Pulmonary artery

Heart

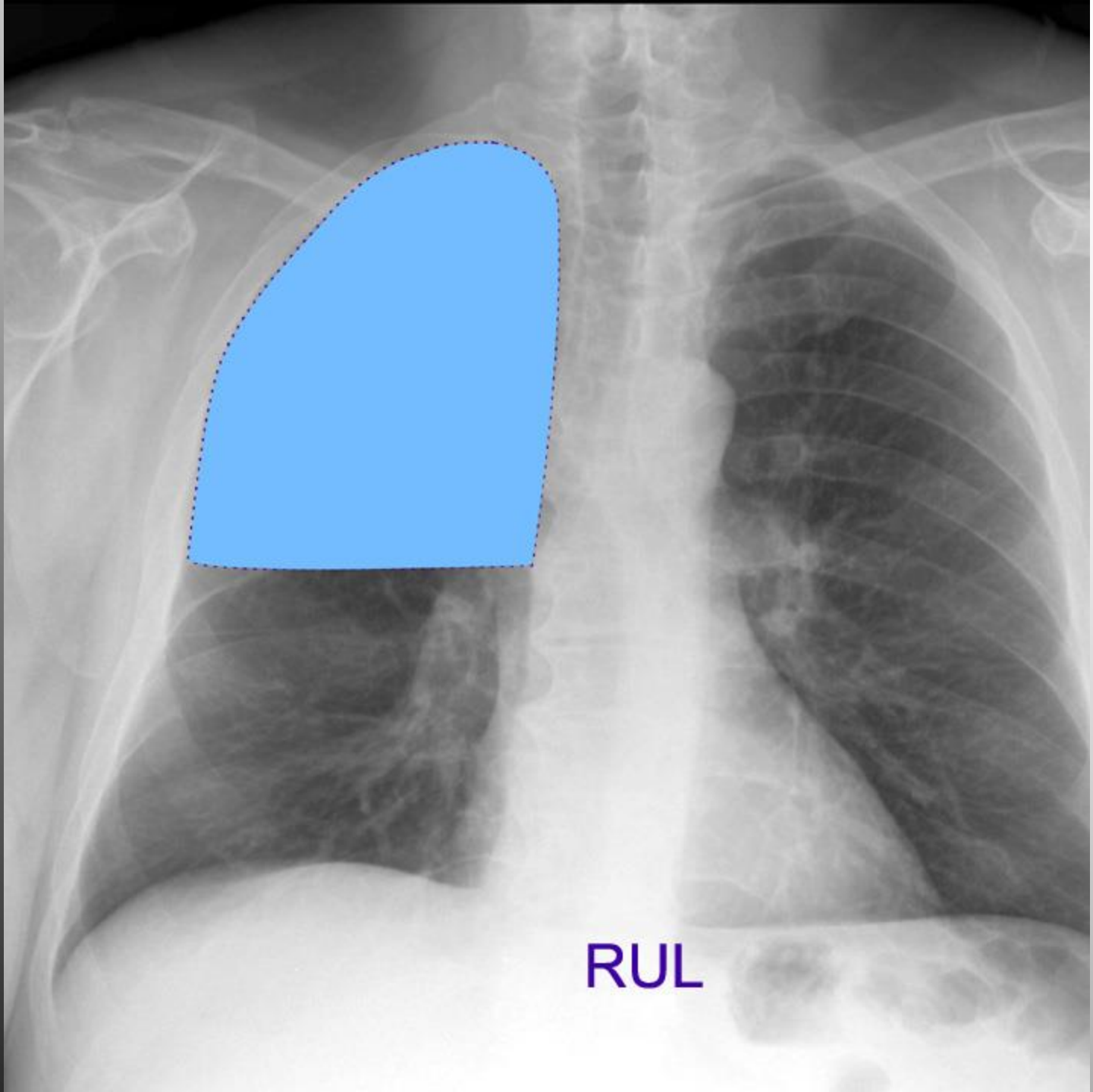
Se.2
Im.1



Rt diaphragm

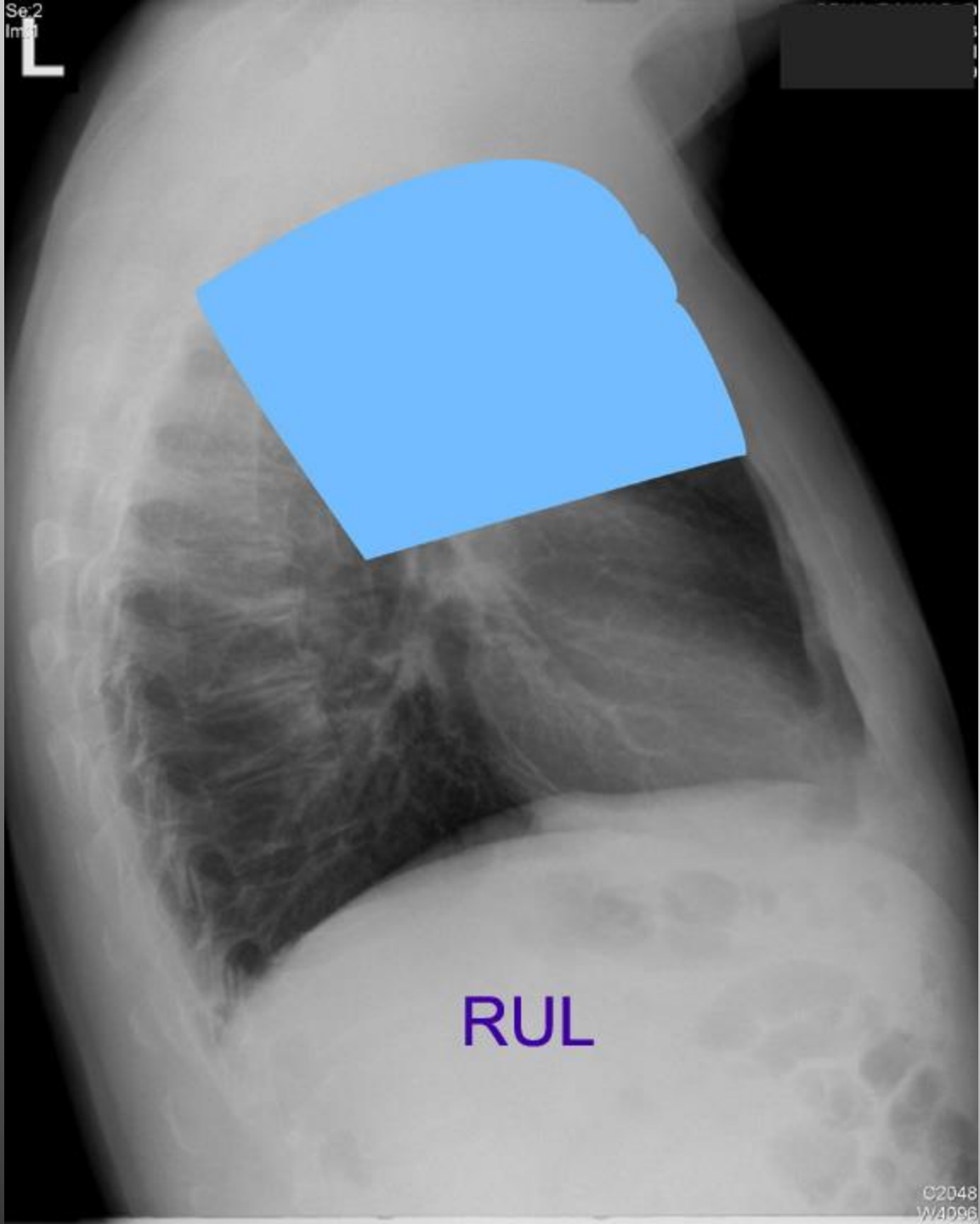
Left diaphragm

Rt Ribs

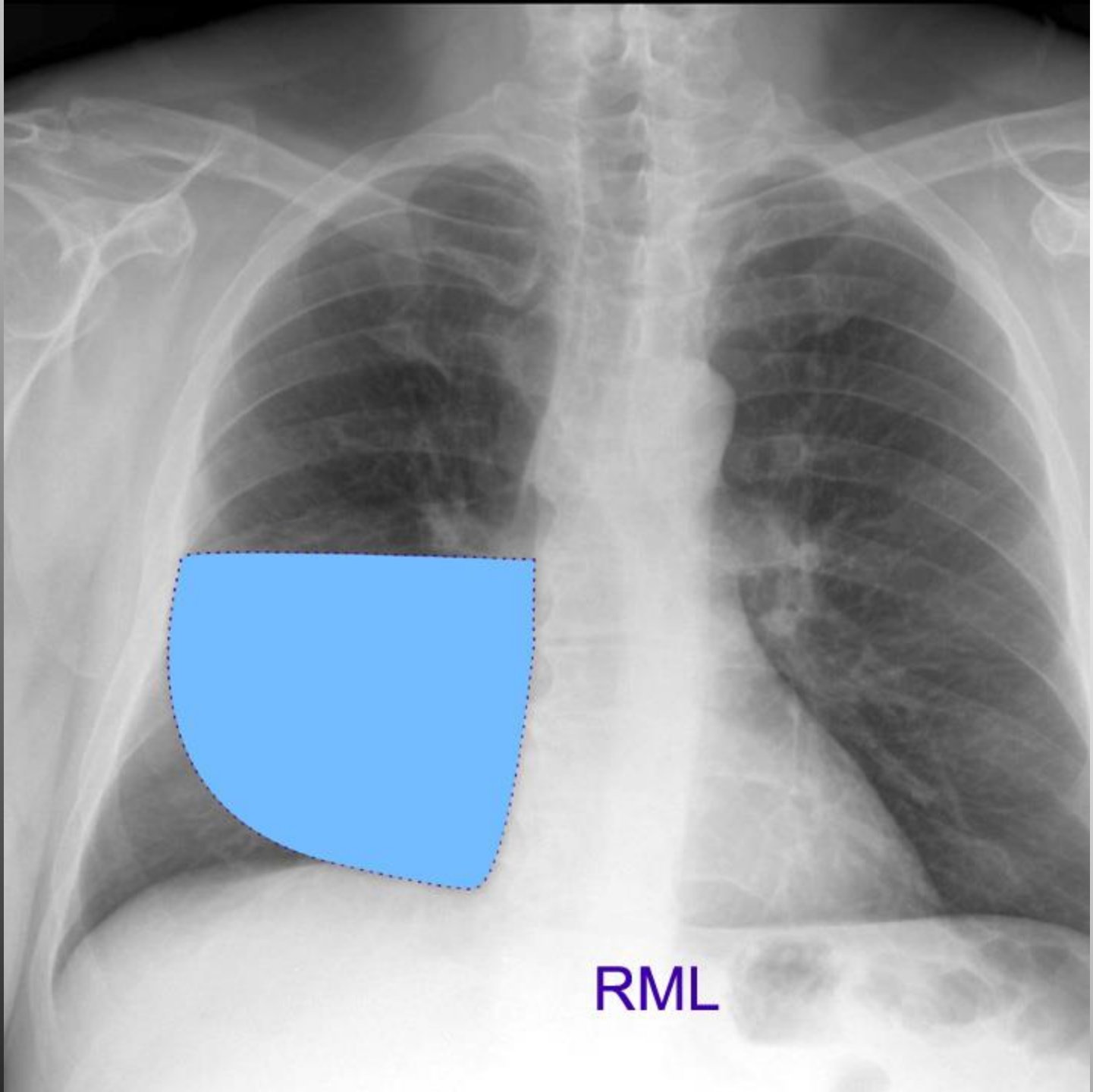


RUL

Se.2
Im.1

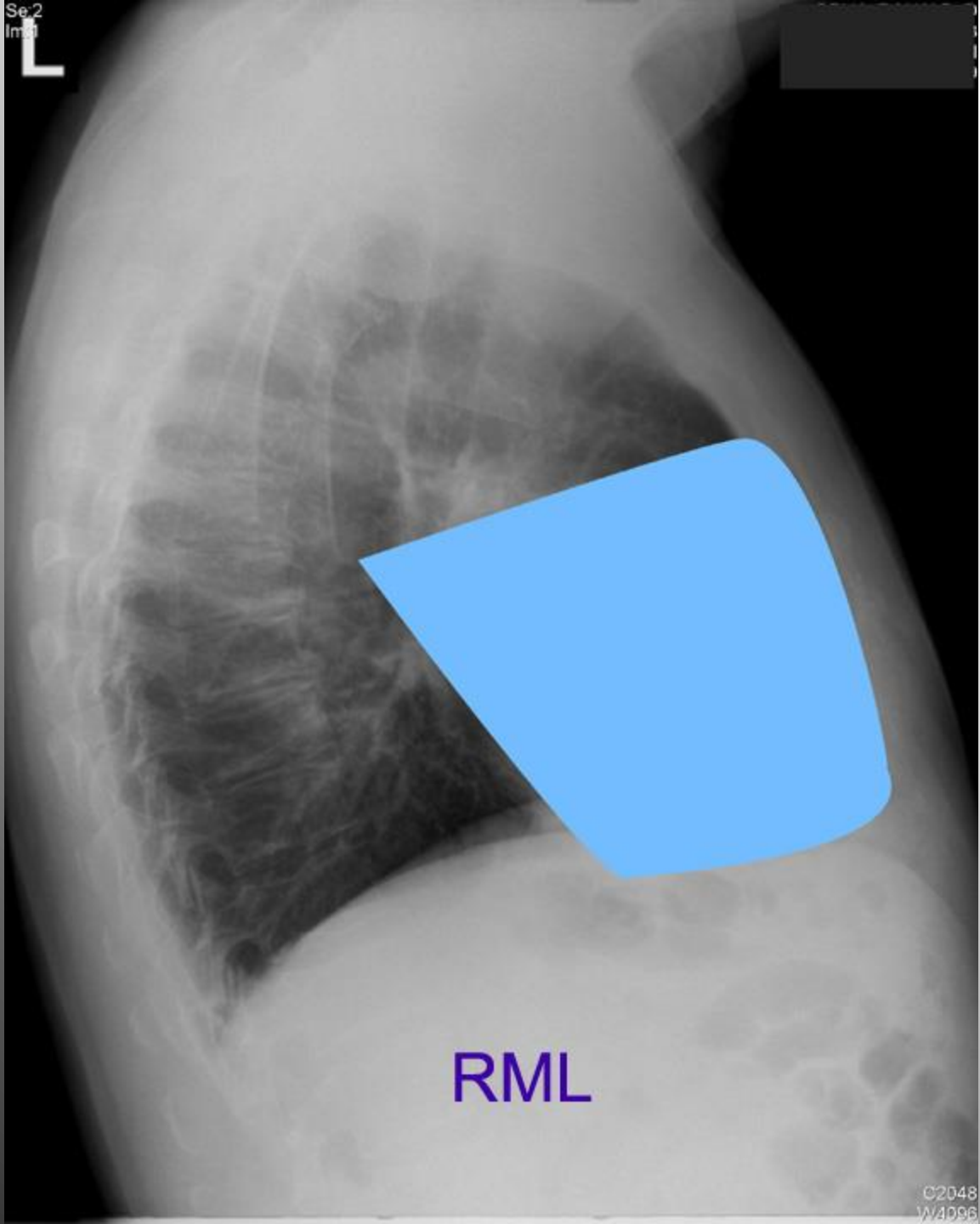


RUL

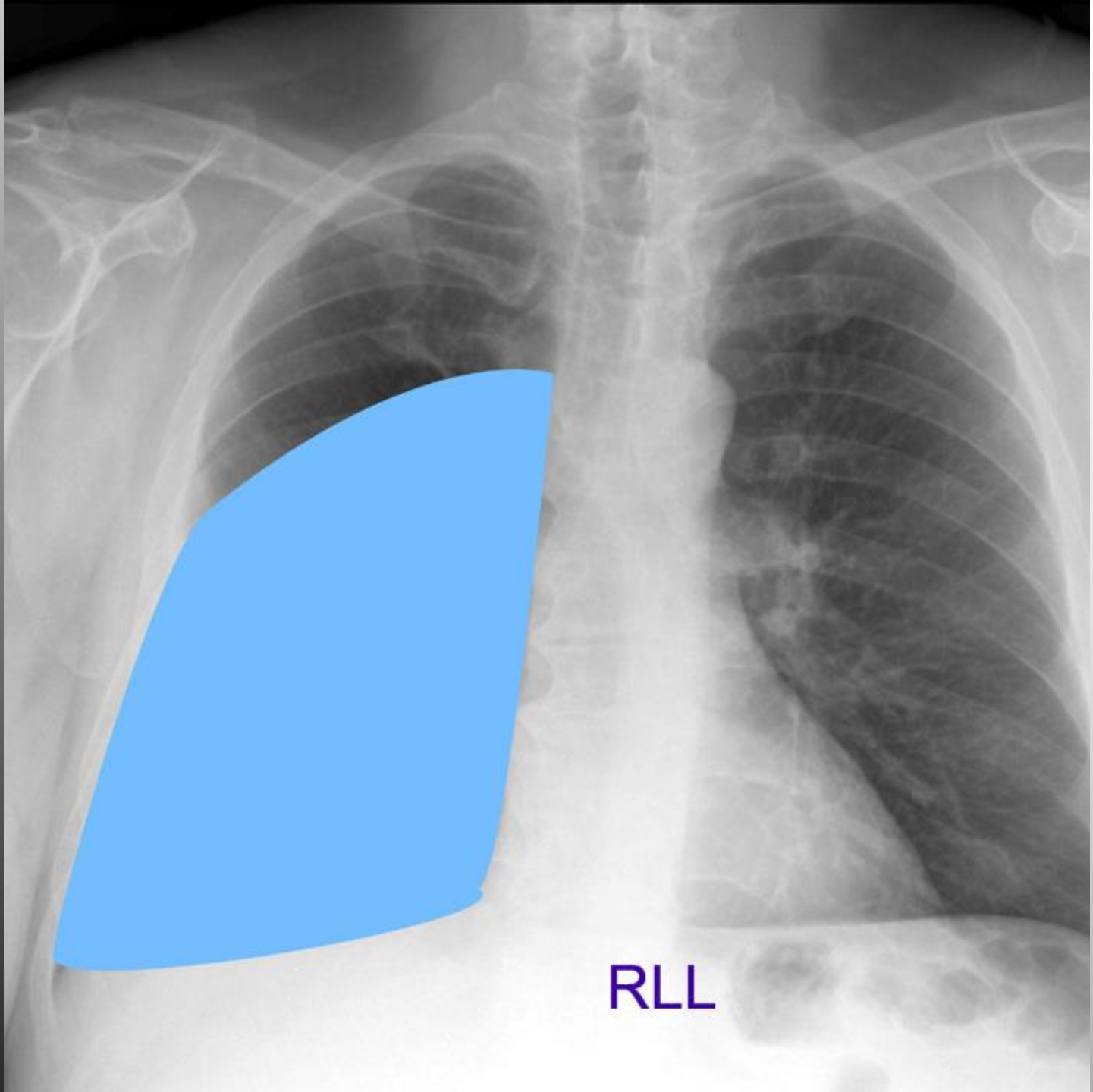


RML

Se.2
Im.1

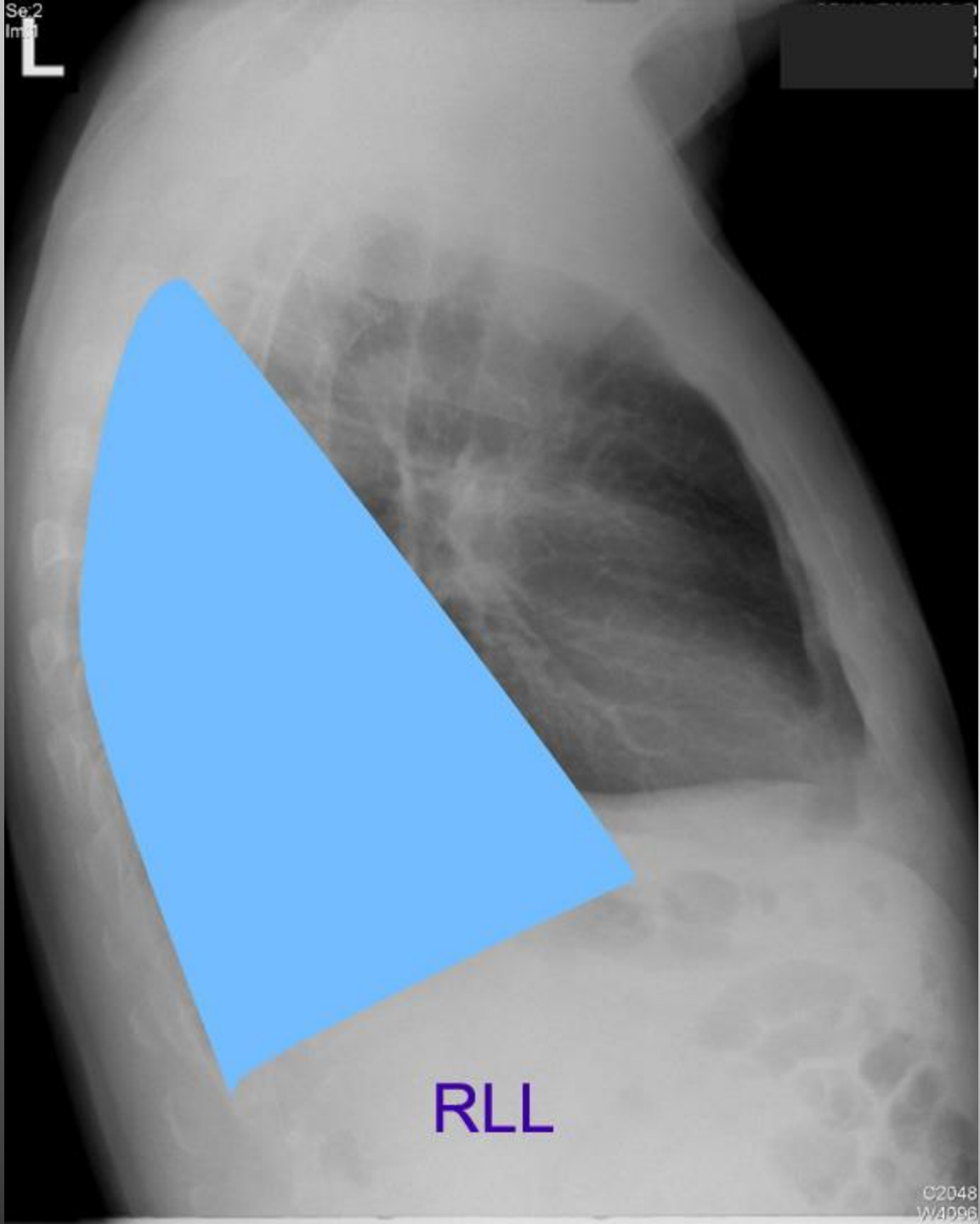


RML

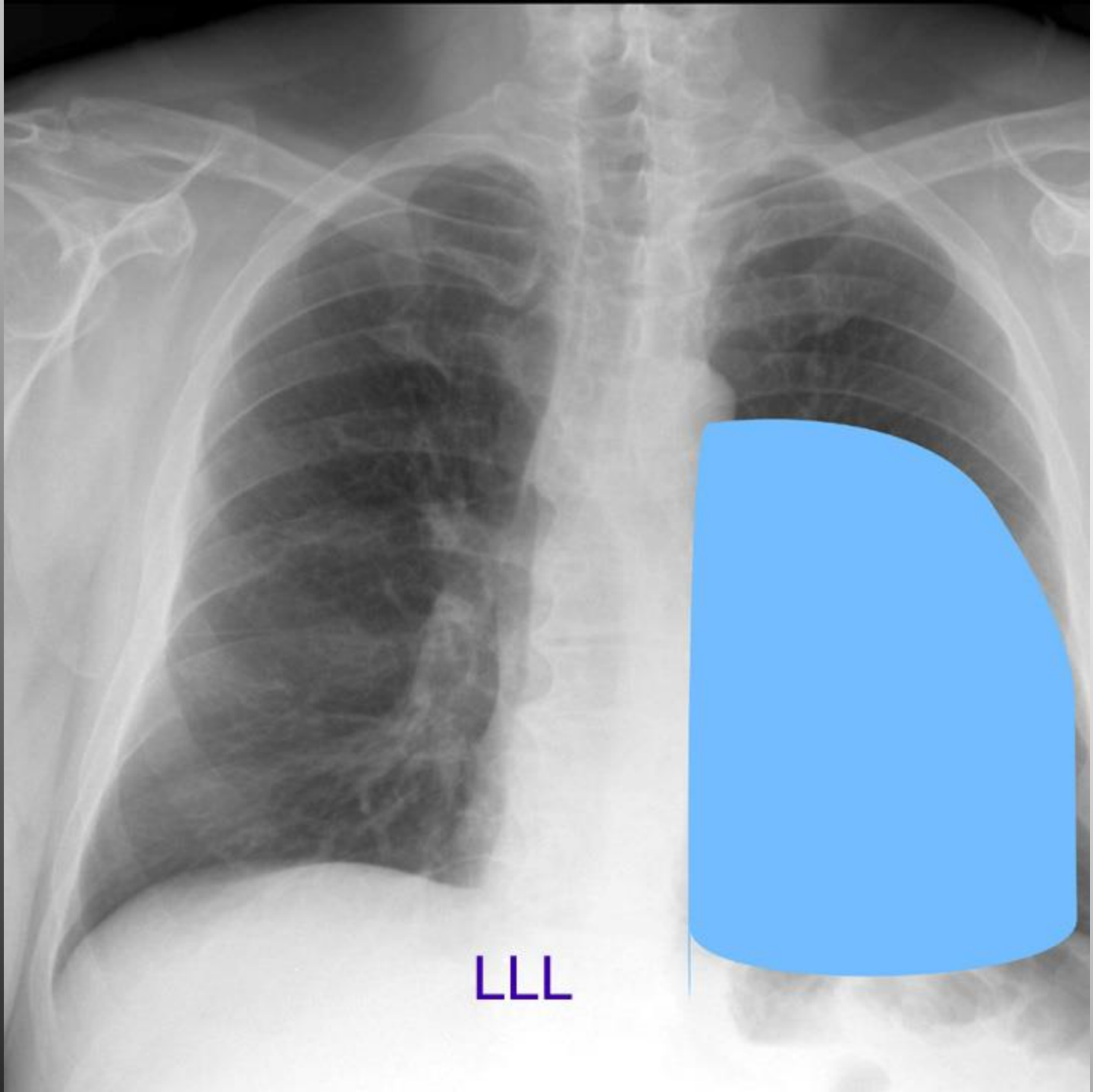


RLL

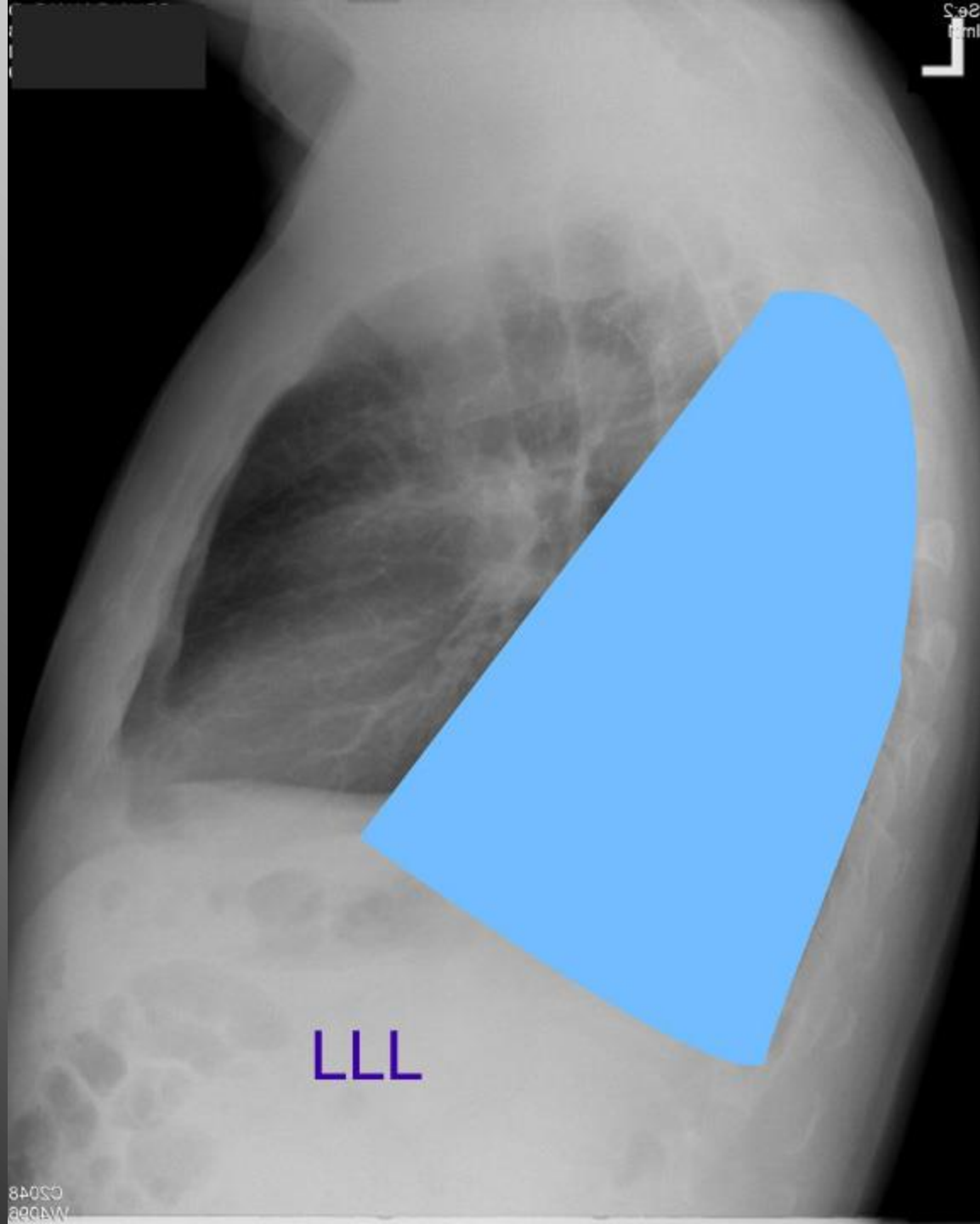
Se.2
Im.1



RLL



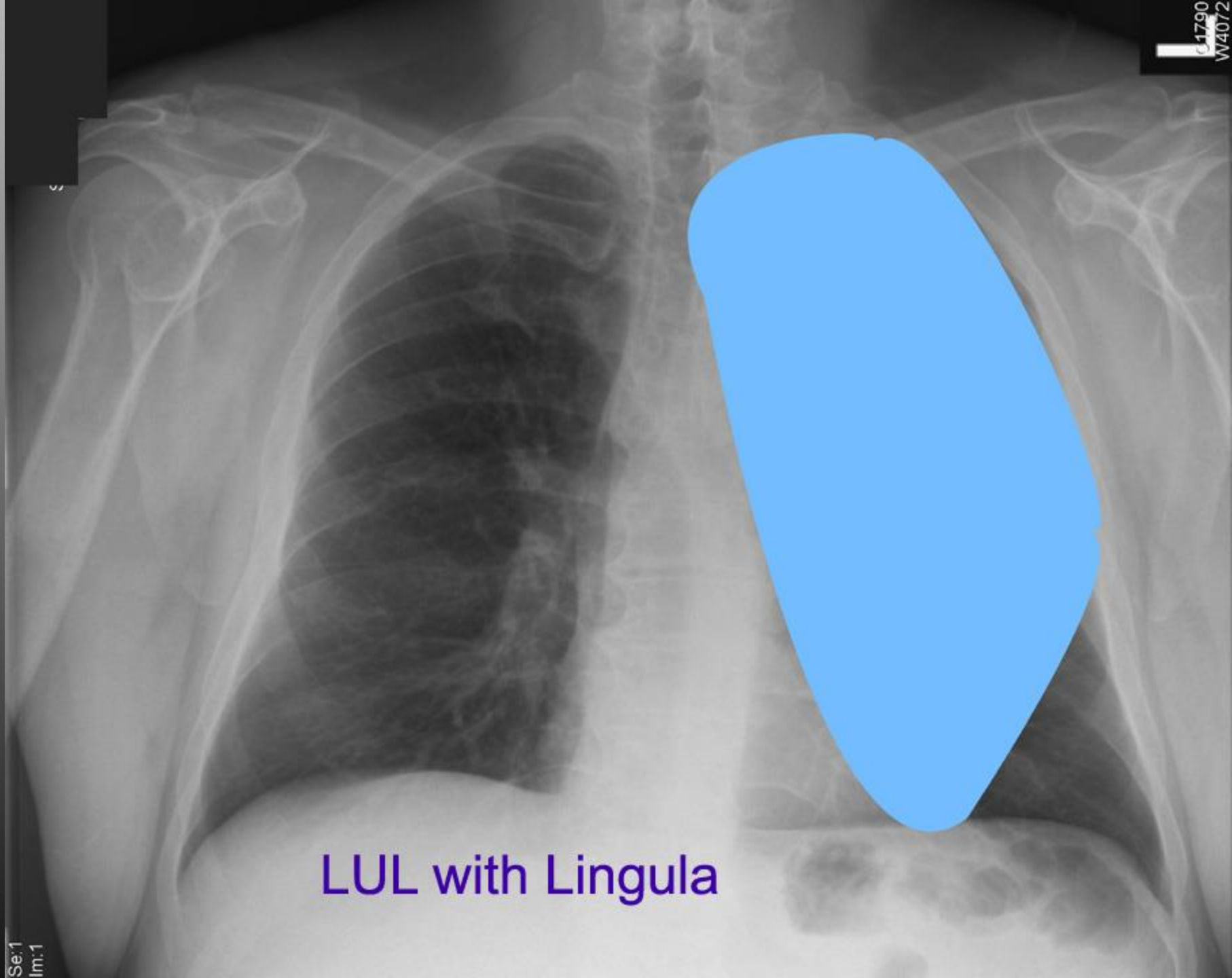
LLL



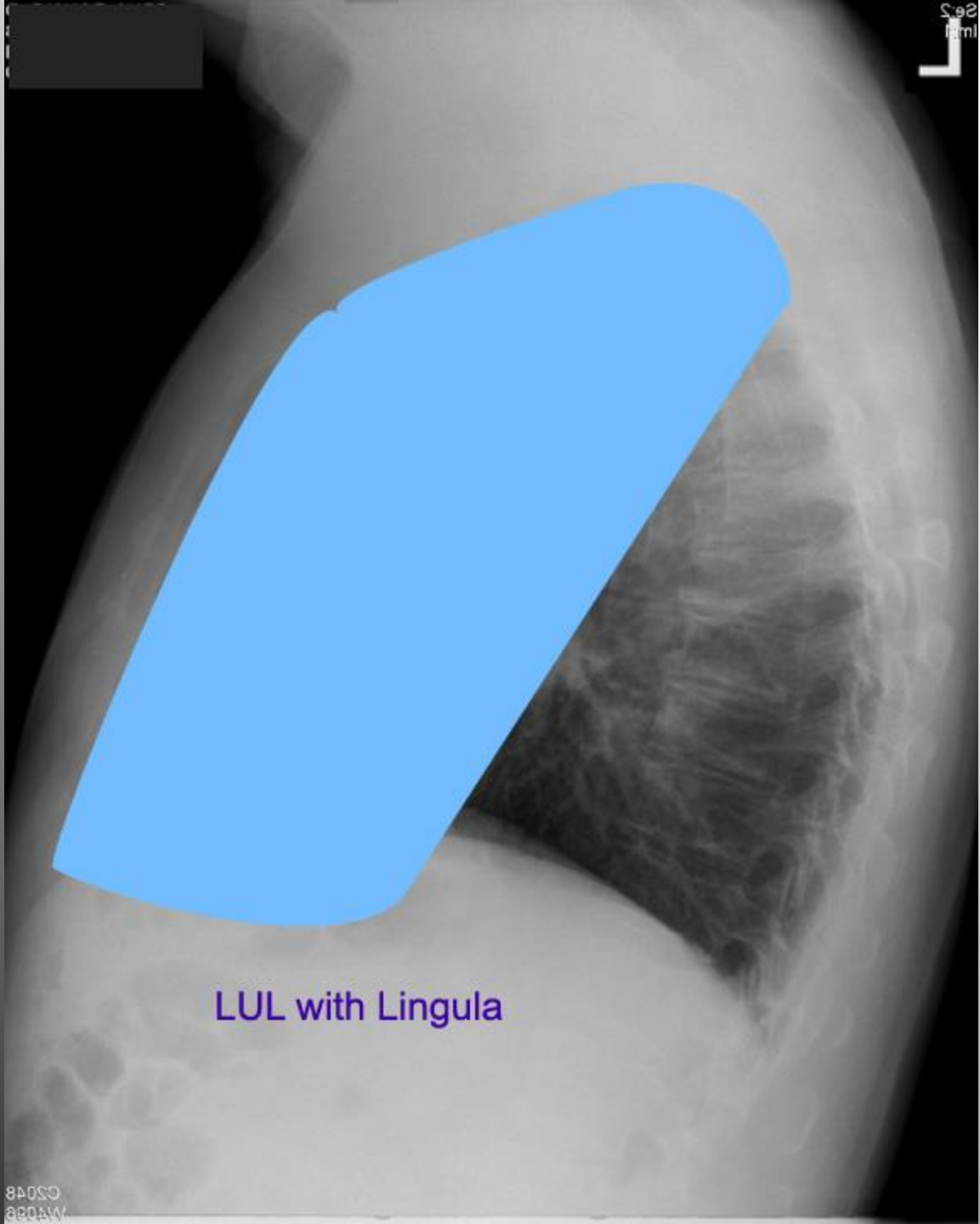
Case
1111

LLL

84050
111111

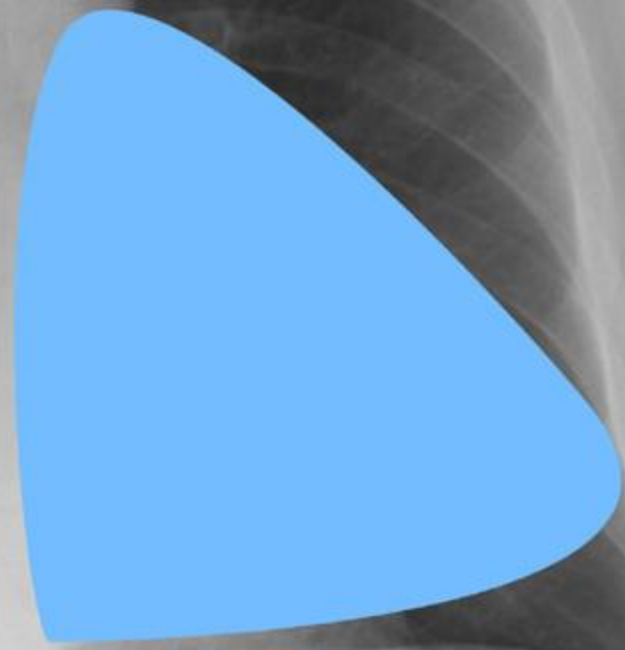


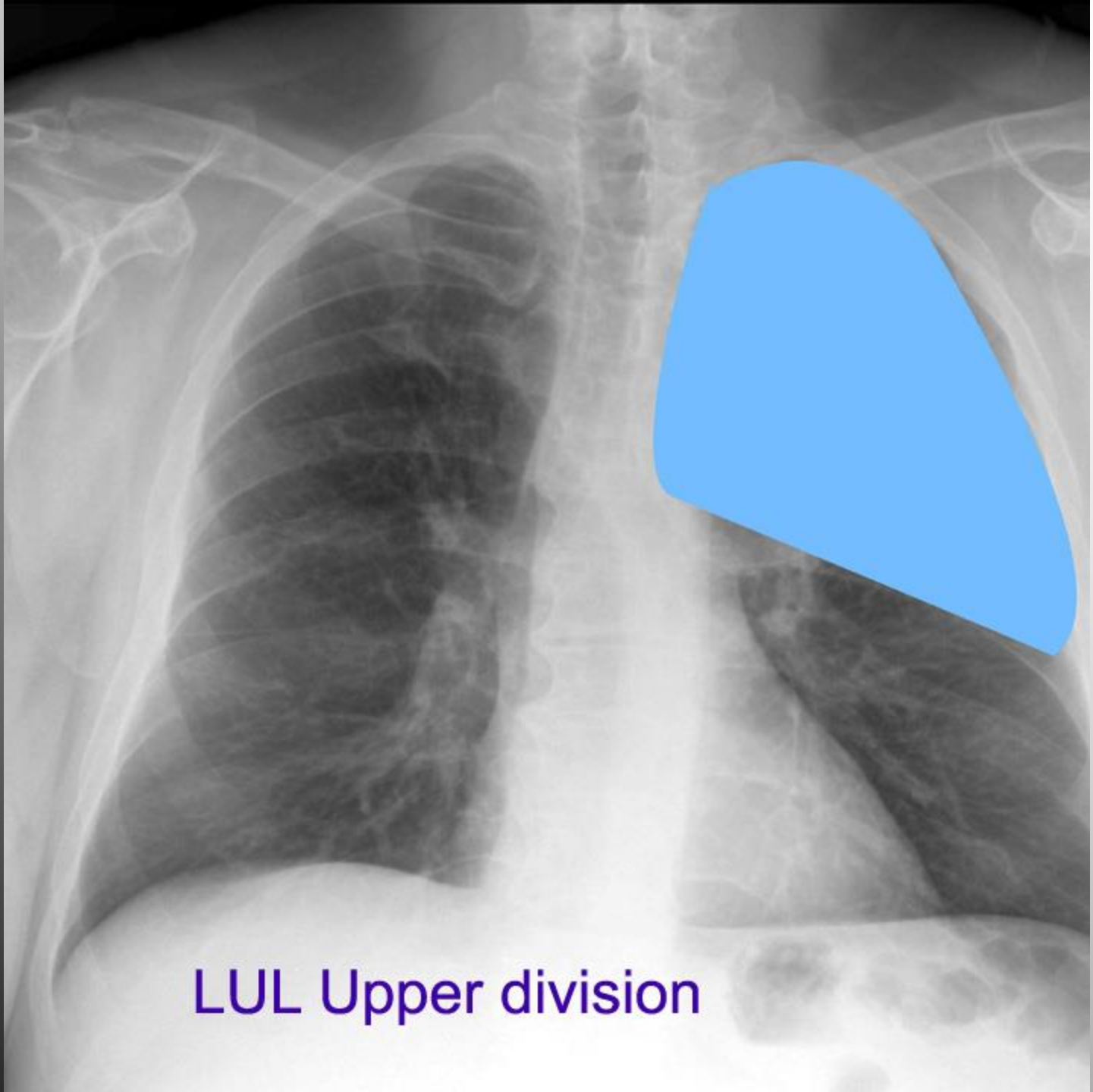
LUL with Lingula



LUL with Lingula

Lingula





LUL Upper division

*Likely the **most common** clinical abnormalities to present on chest x-ray...*

Pneumothorax

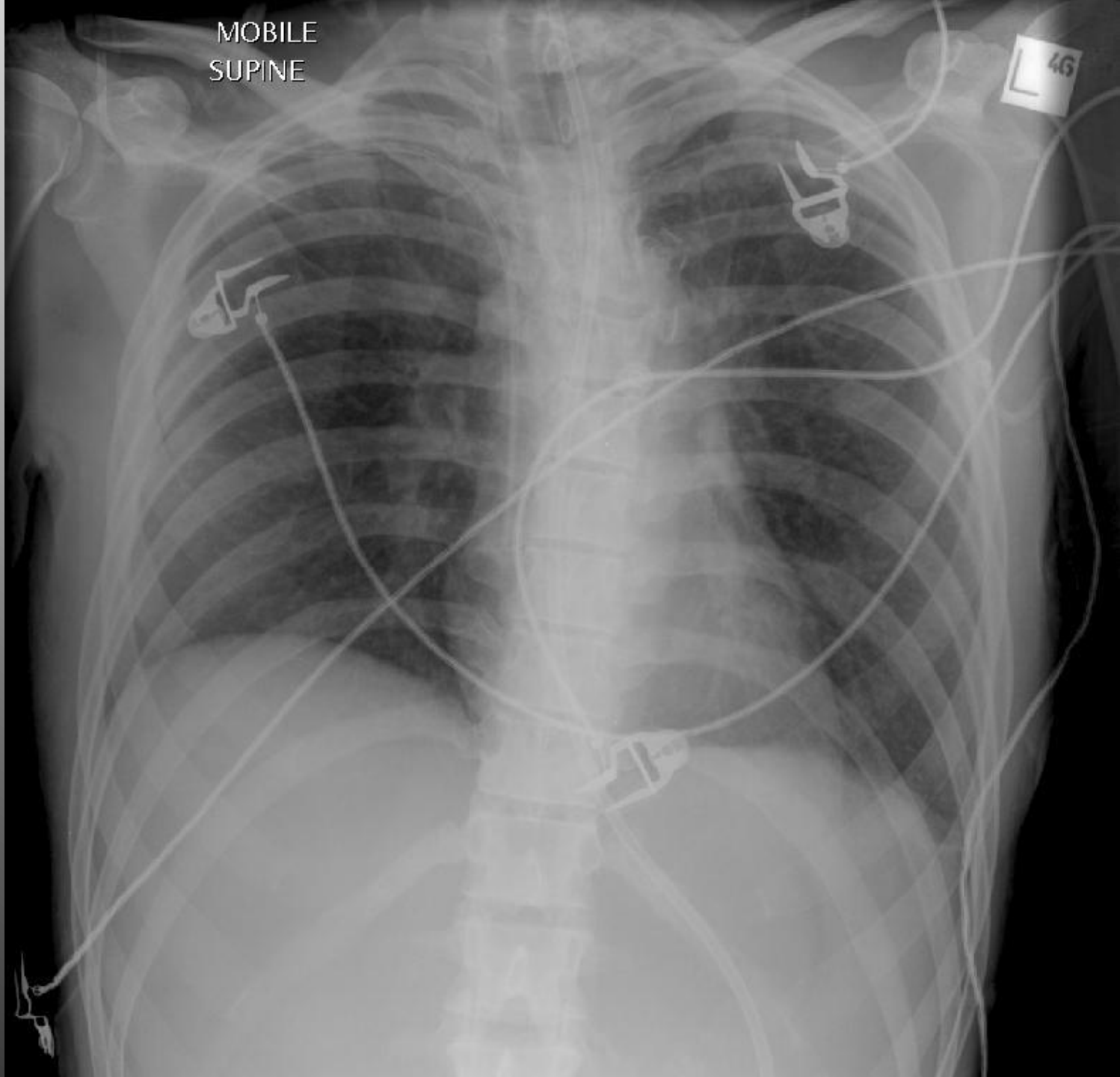Atelectasis/Consolidation/Pneumonia

Pleural Effusion

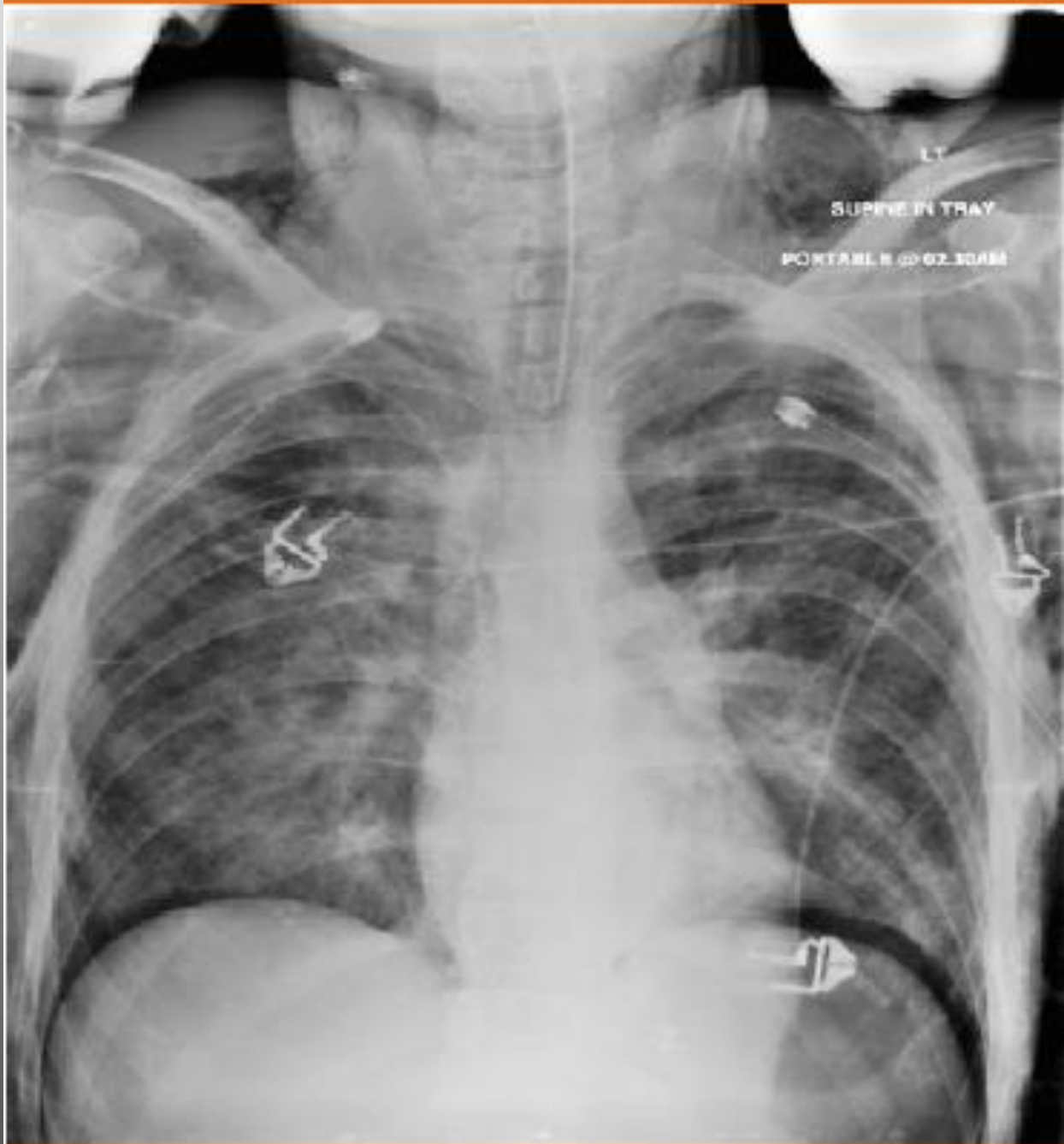
Lesion/Mass

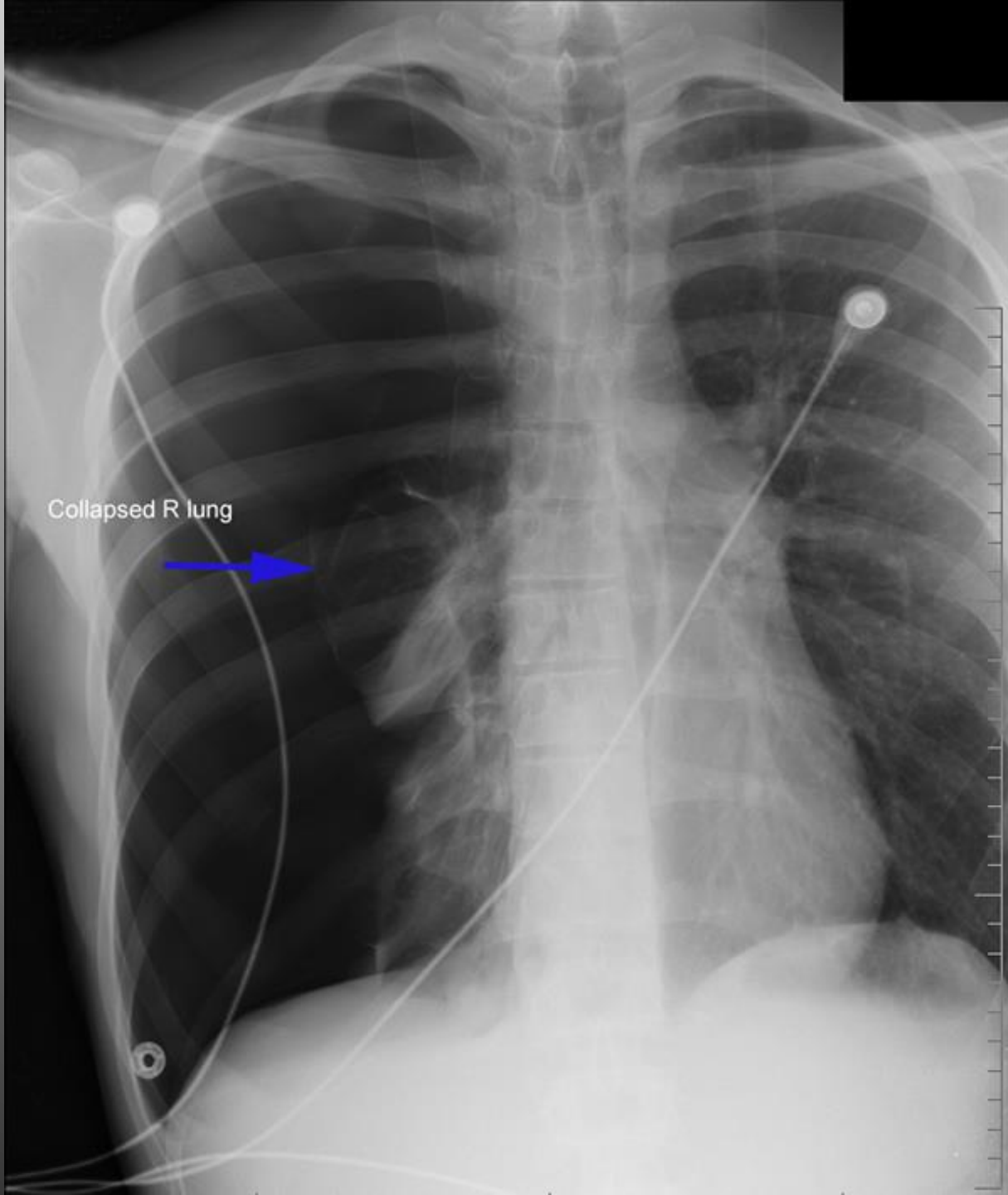
Air Trapping and/or Hyperinflation

39
Male
s/p
MVC



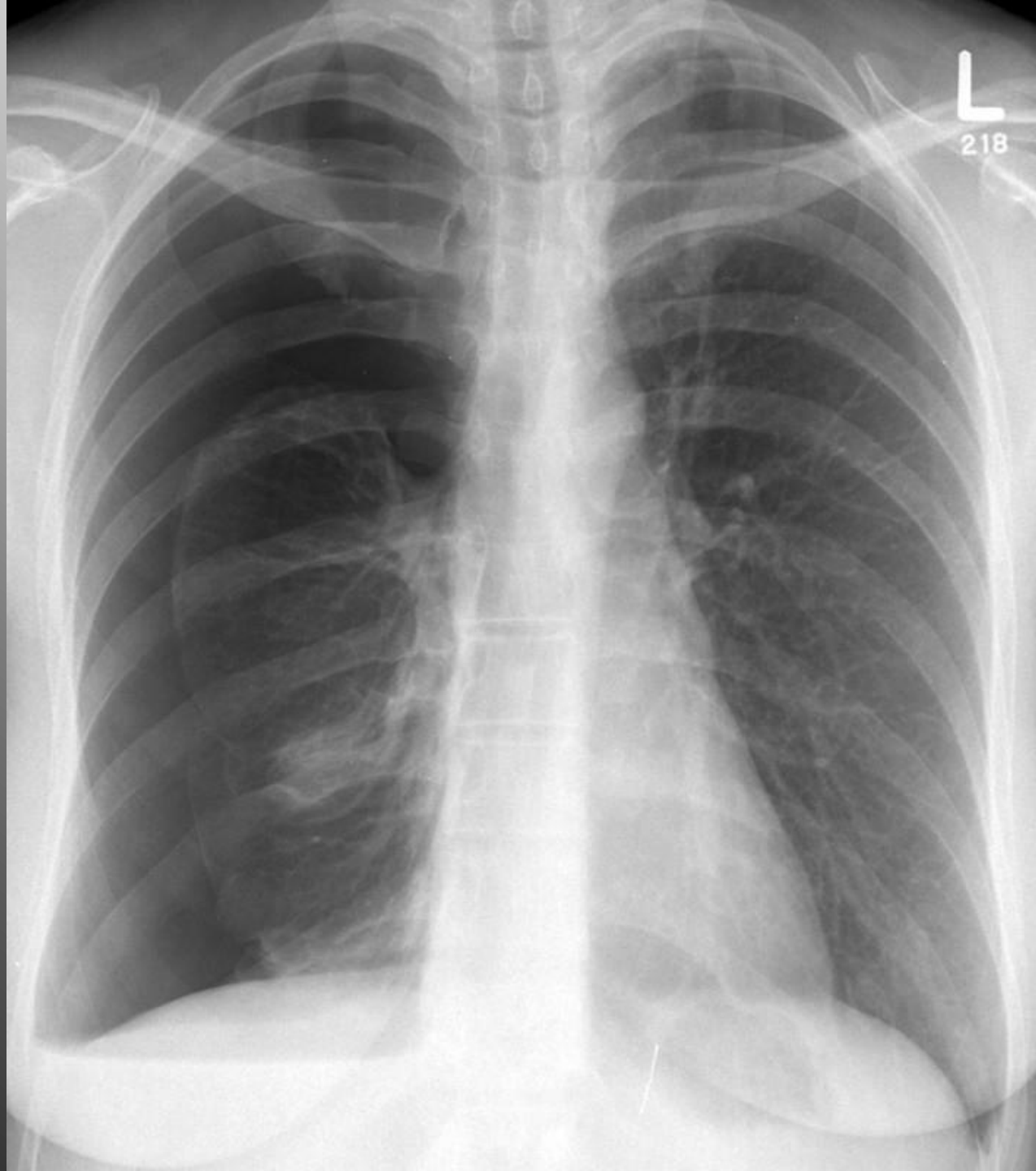ARDS s/p
blunt chest
trauma

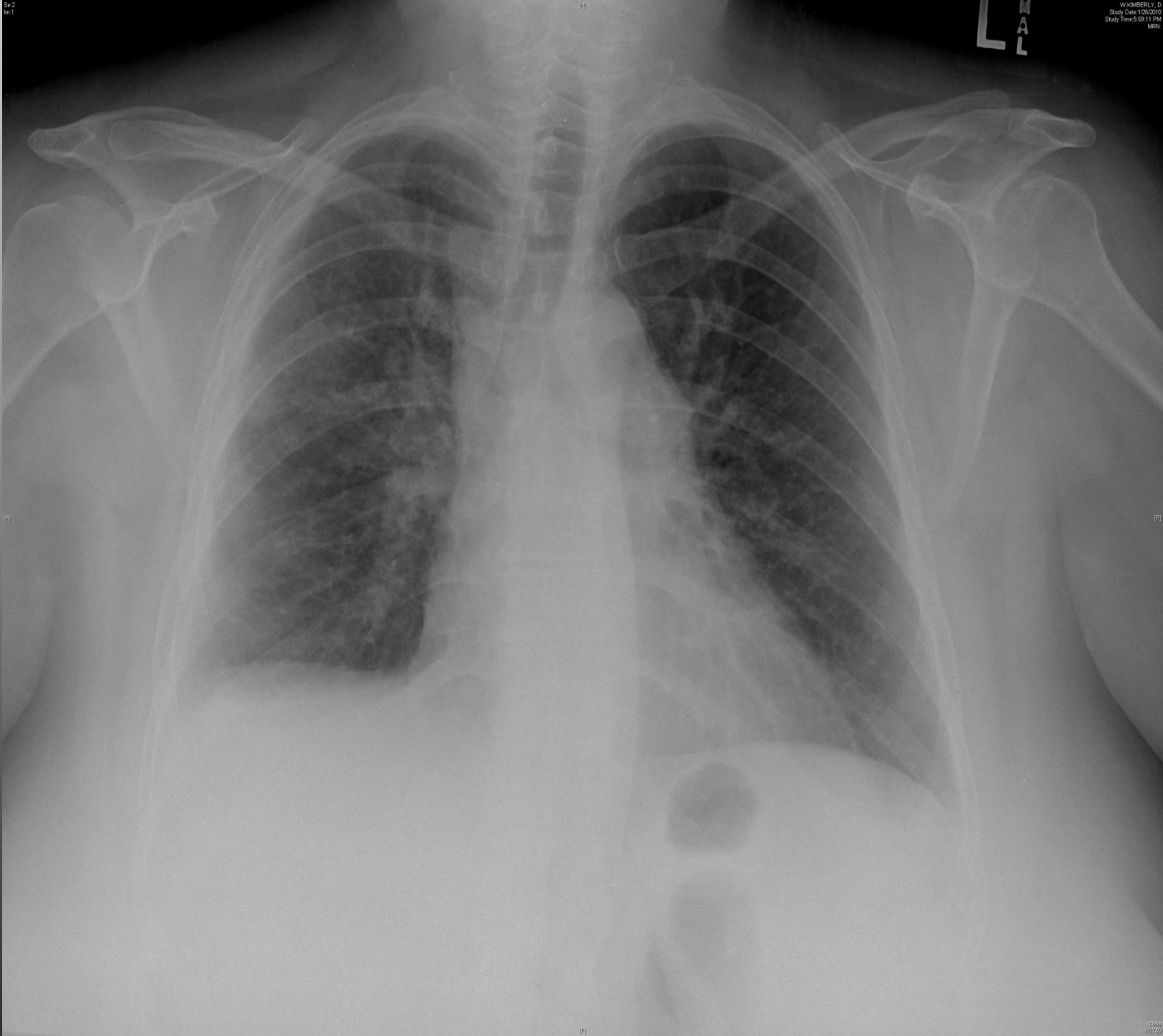


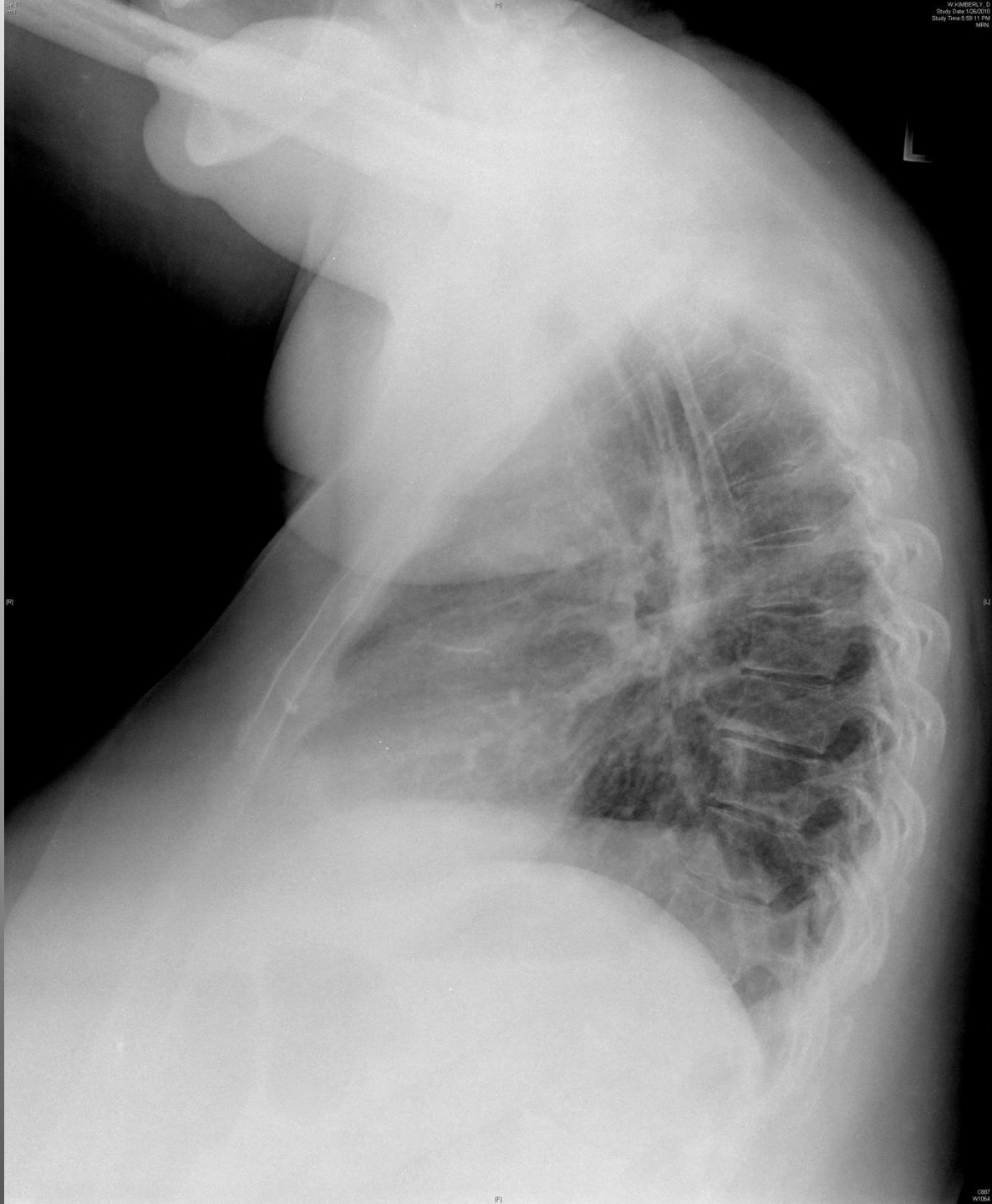


Collapsed R lung





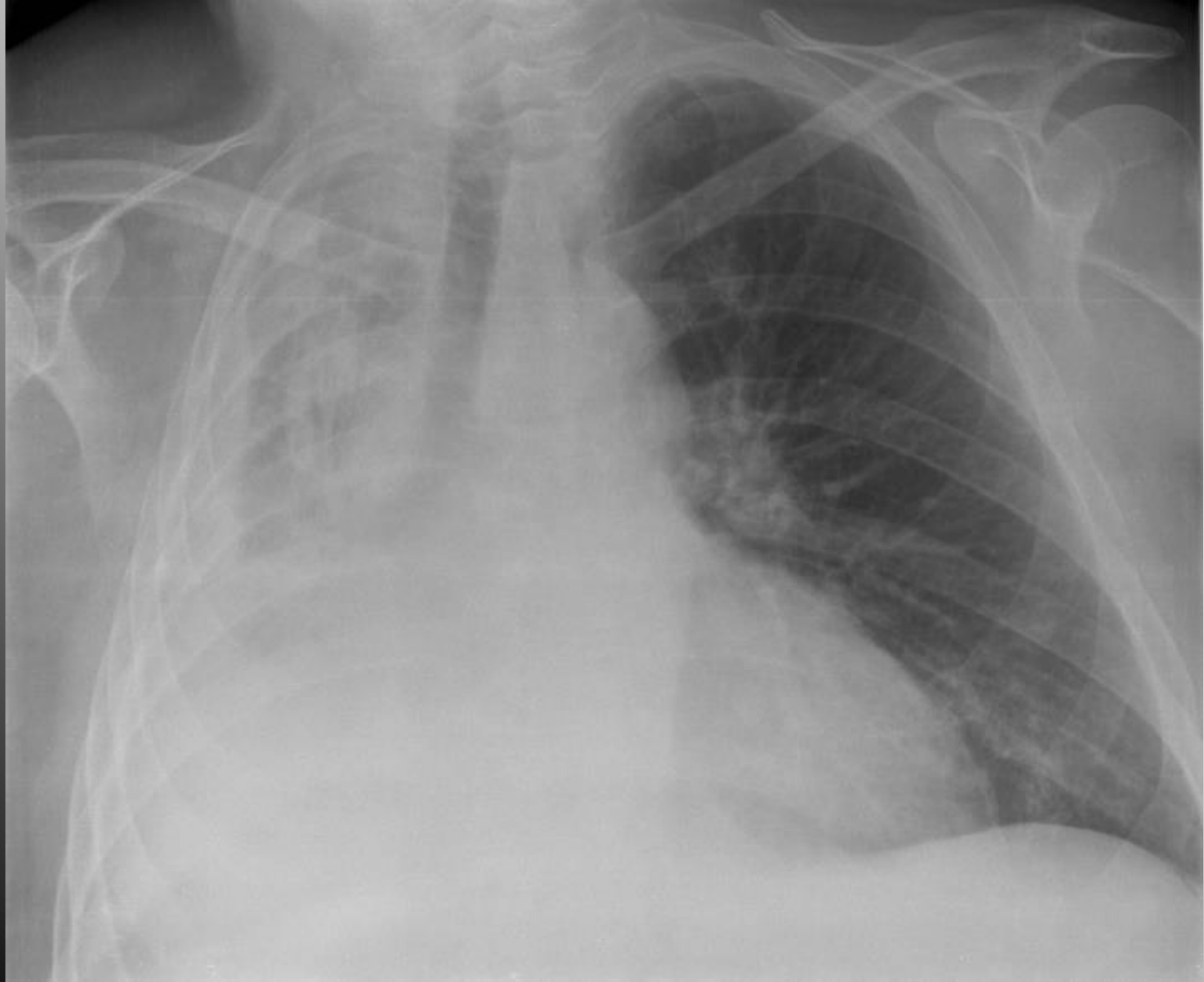



L

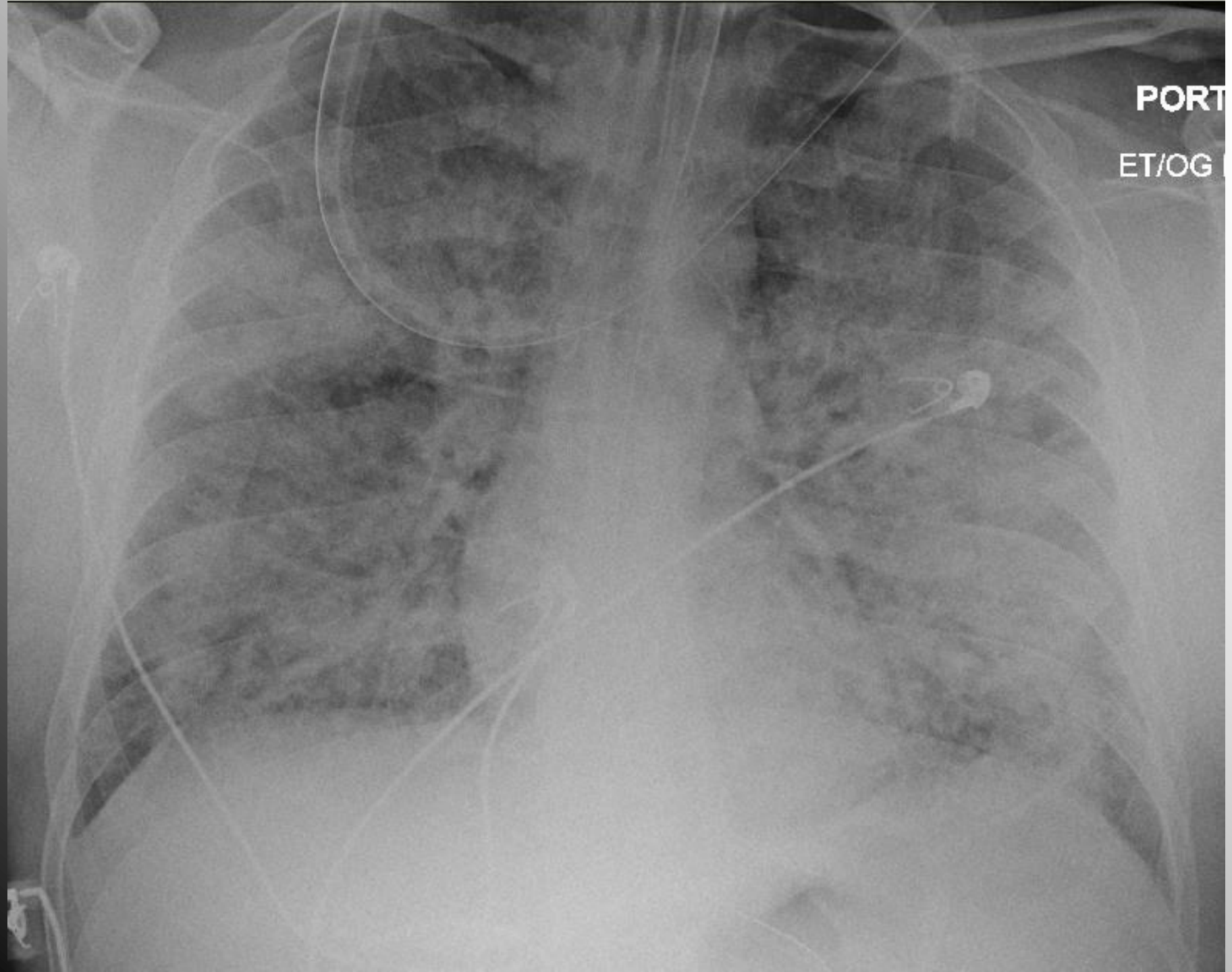
F1

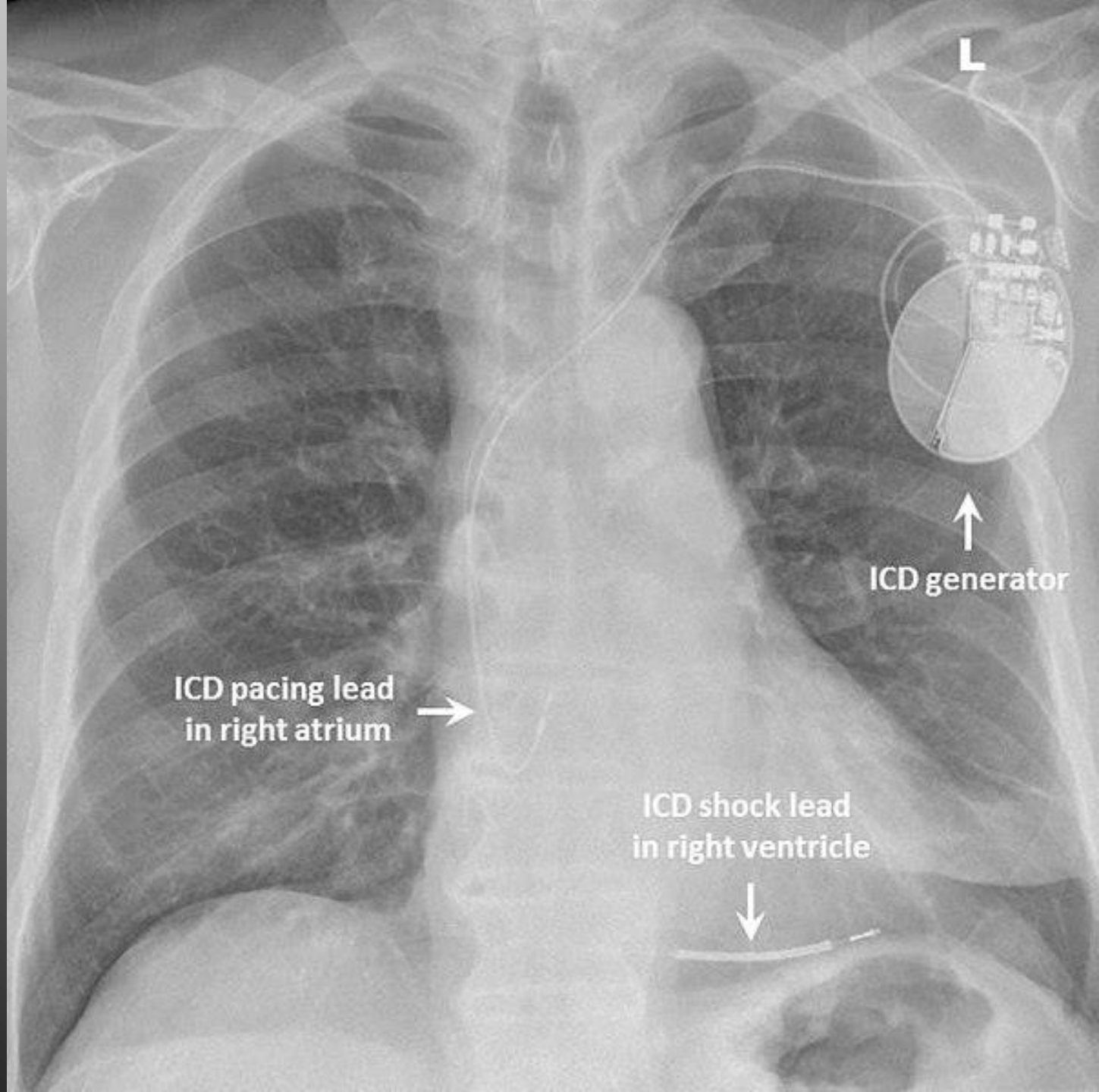
0007
W1064



PORT

ET/OG

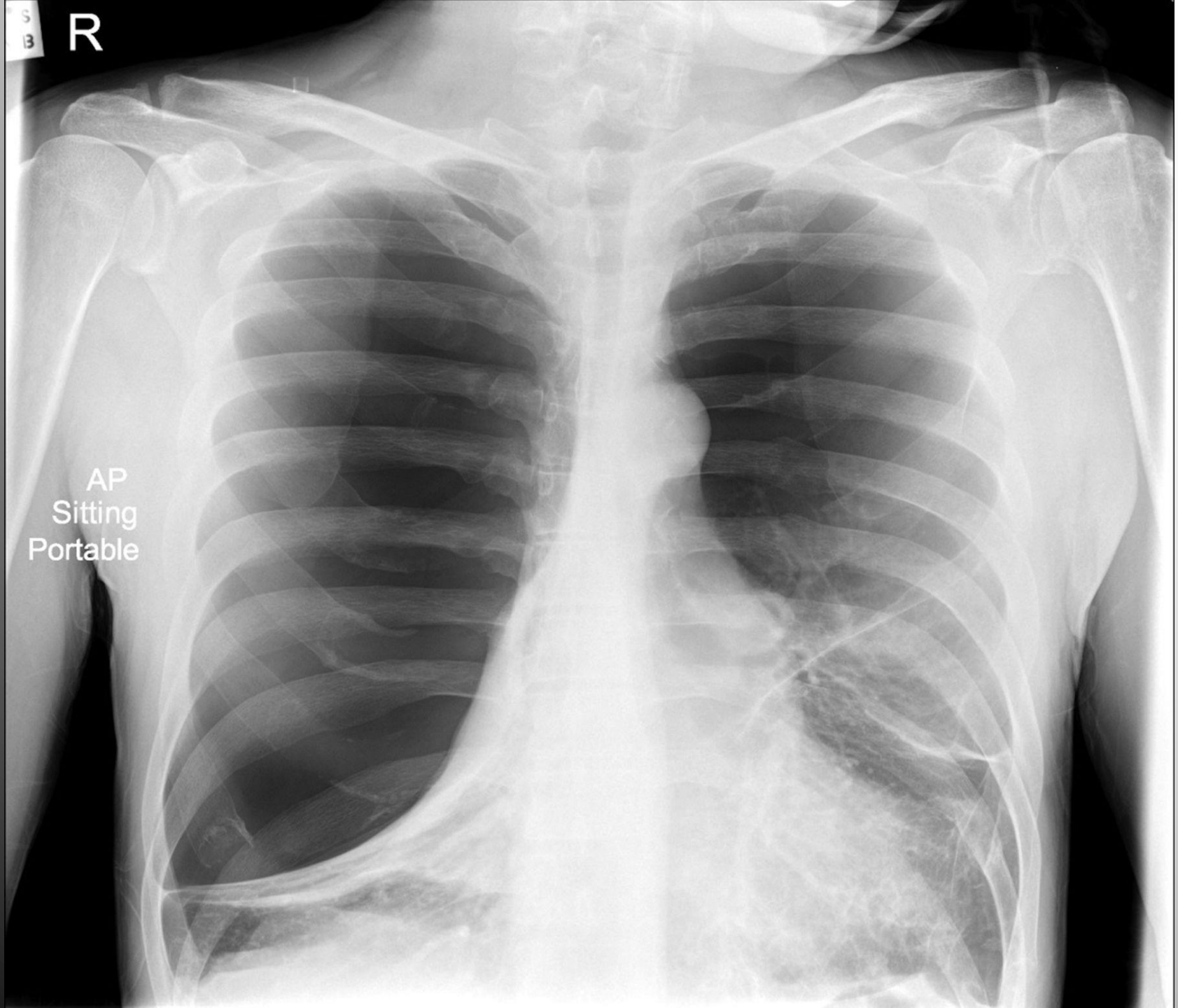


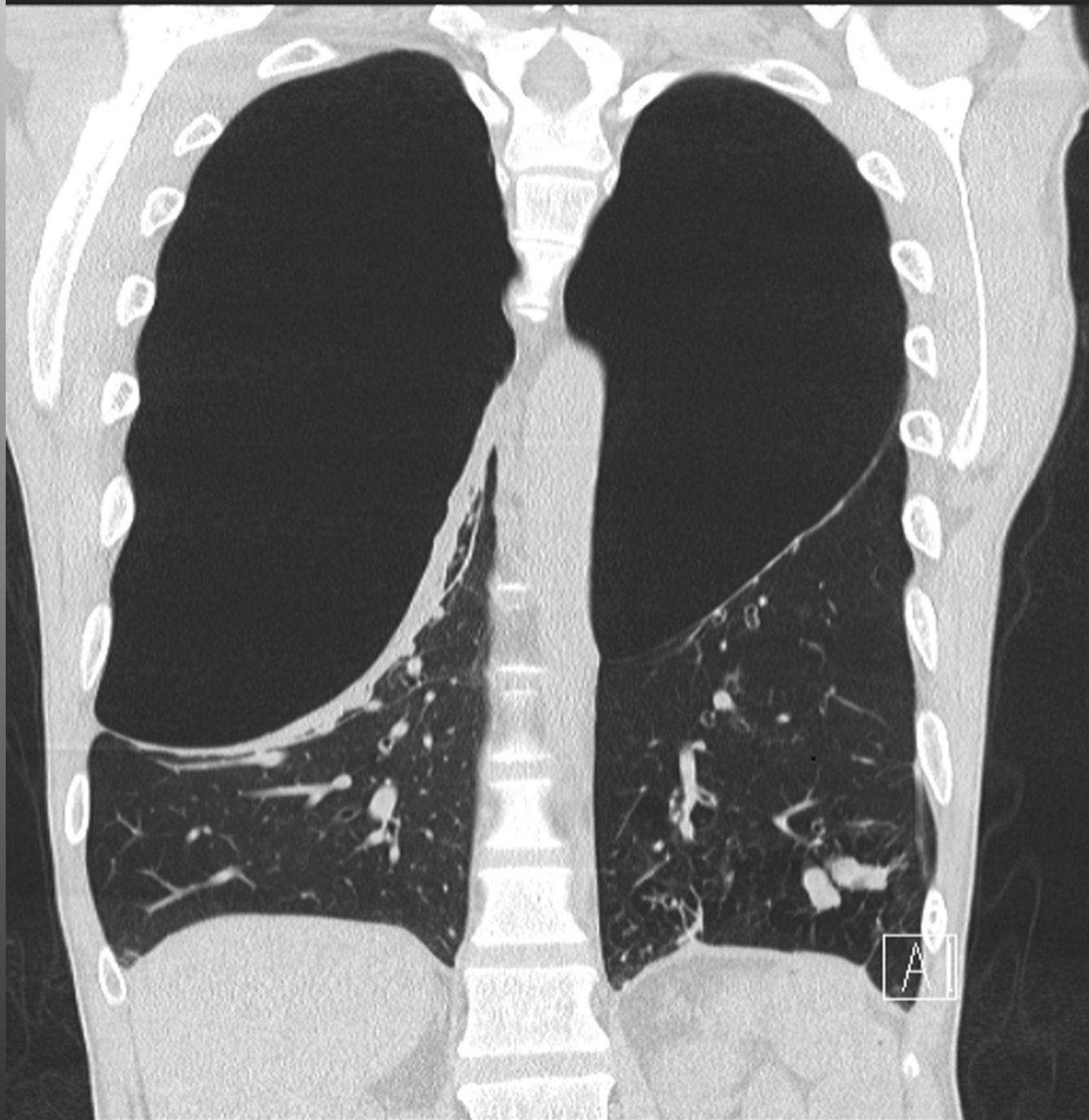

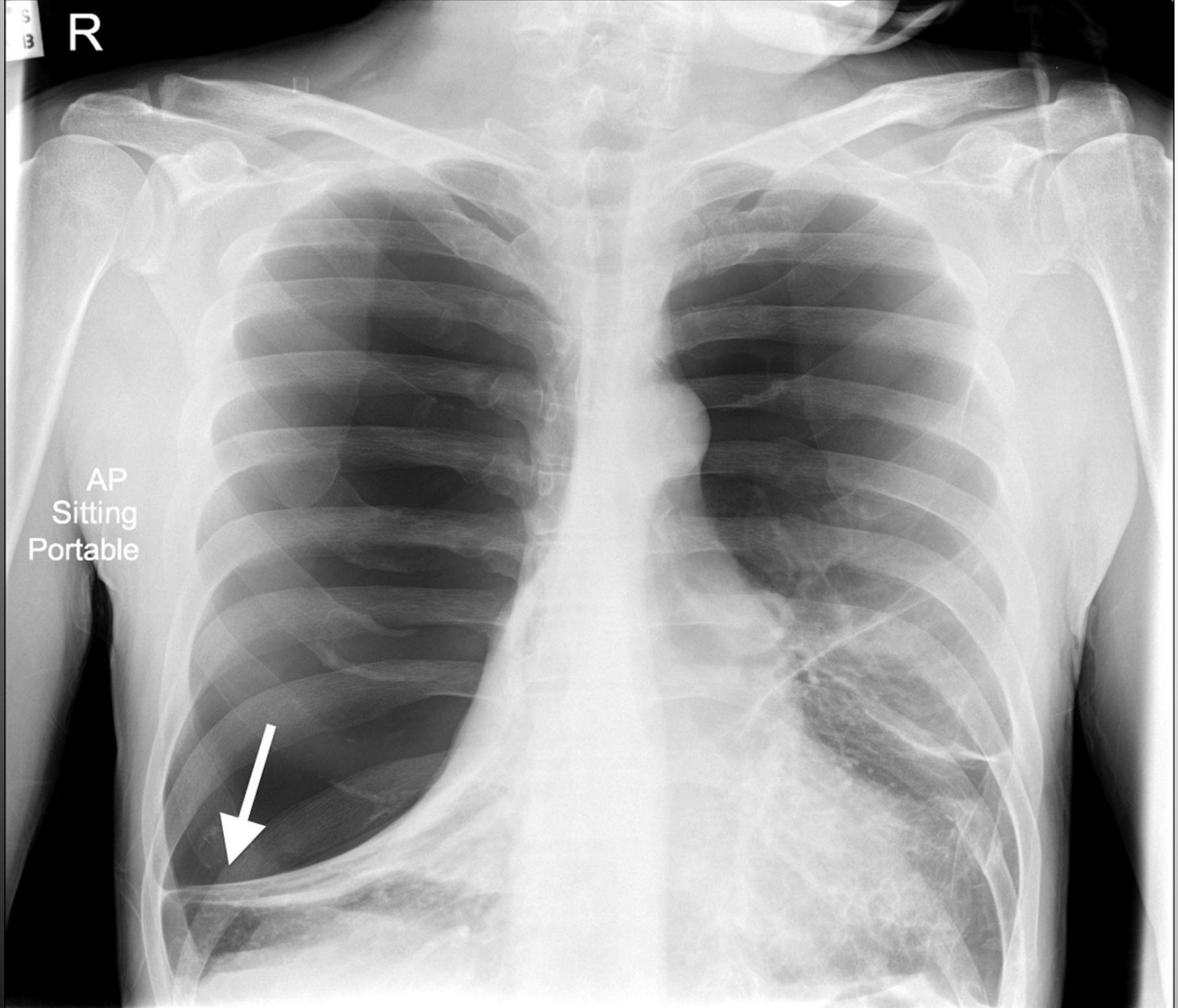
S
B

R

AP
Sitting
Portable

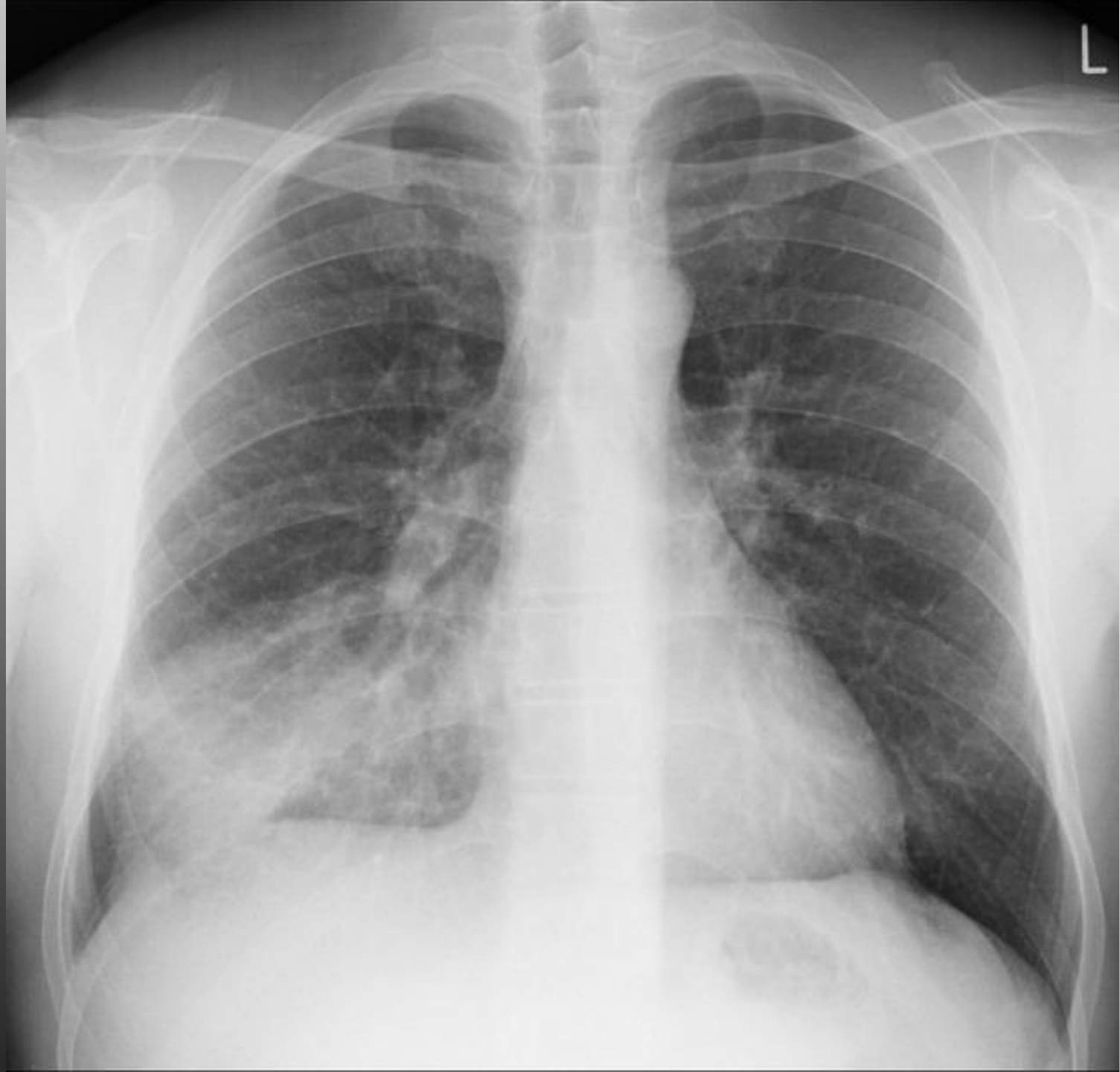


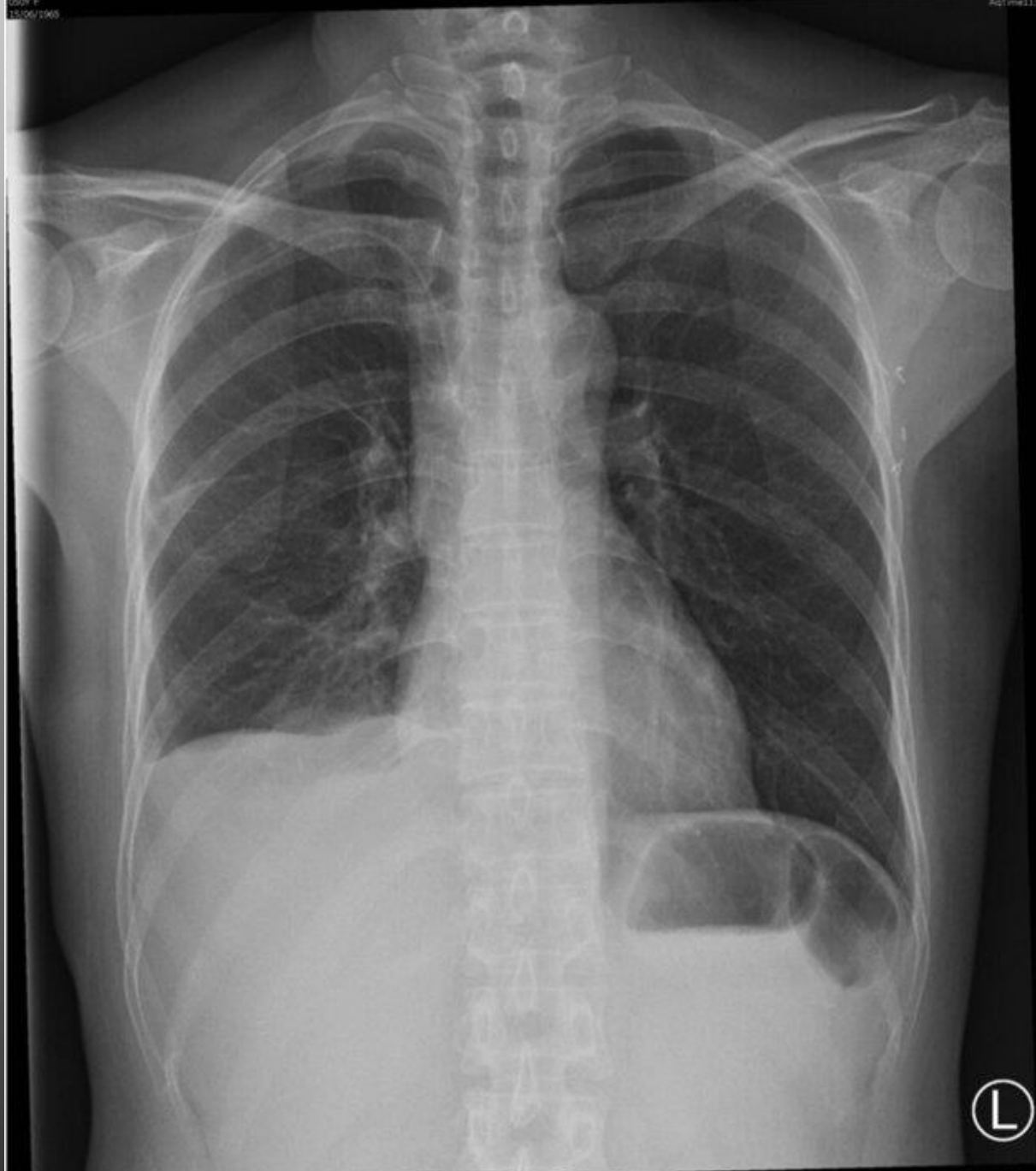




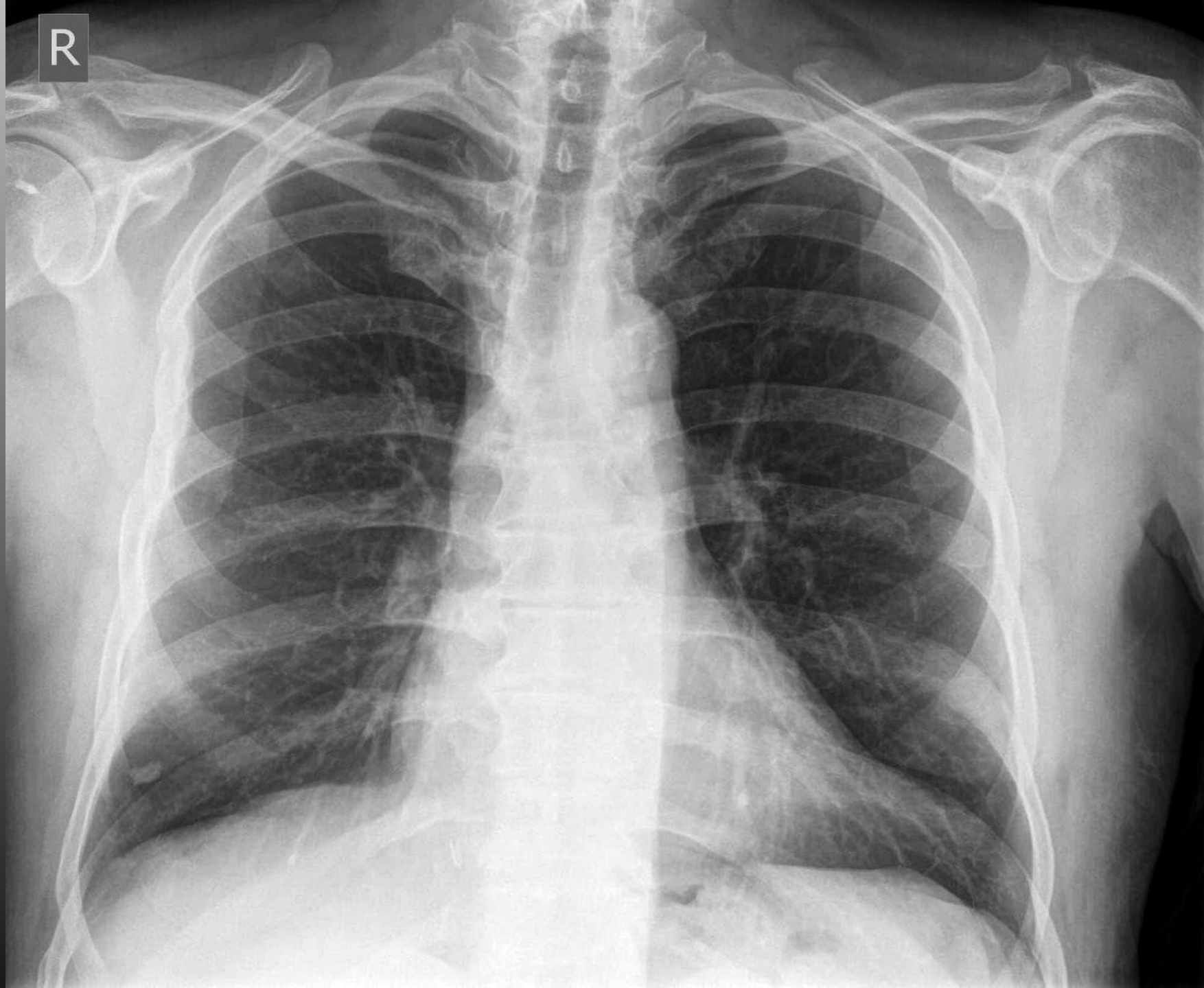
AP
Sitting
Portable

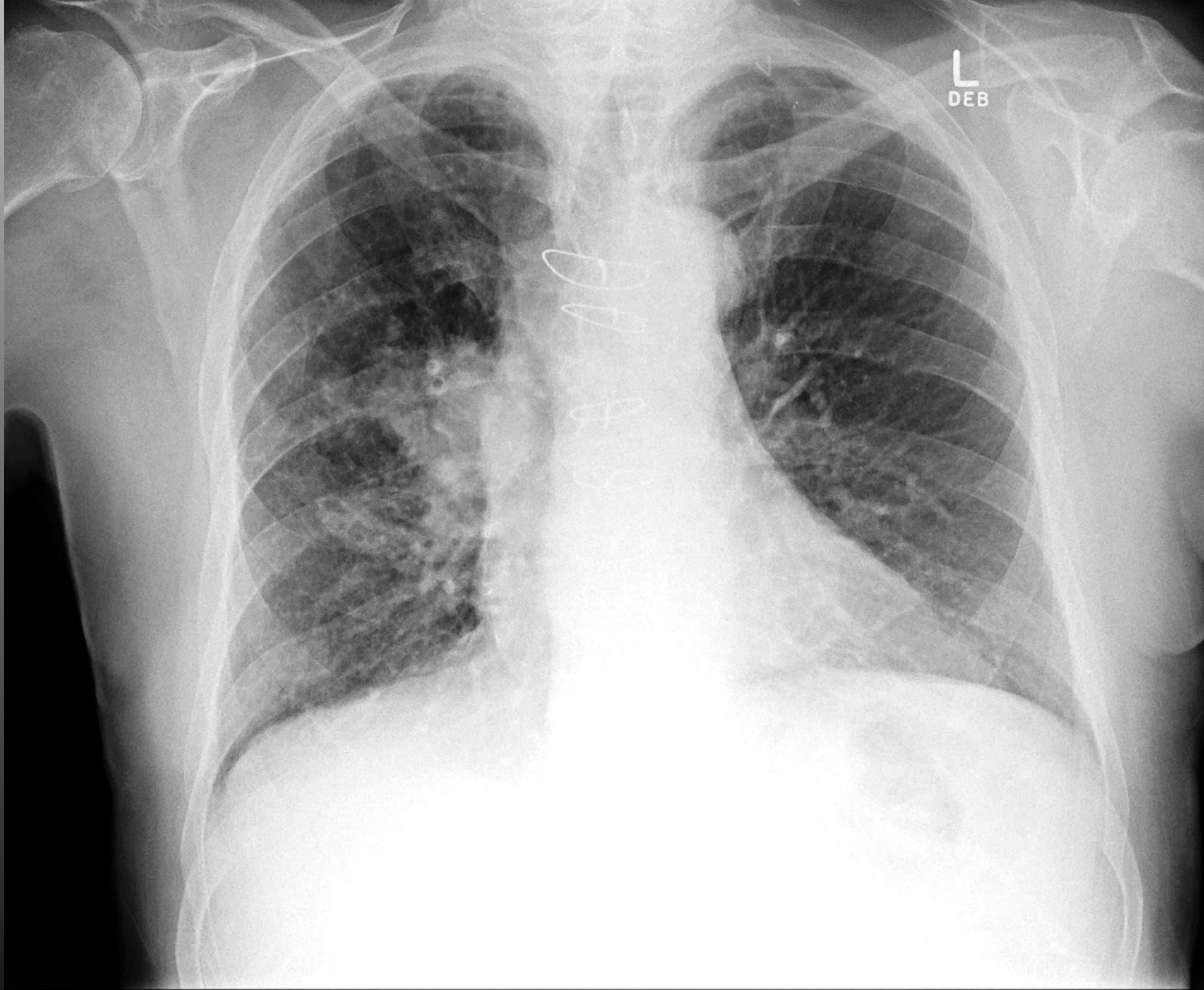
R





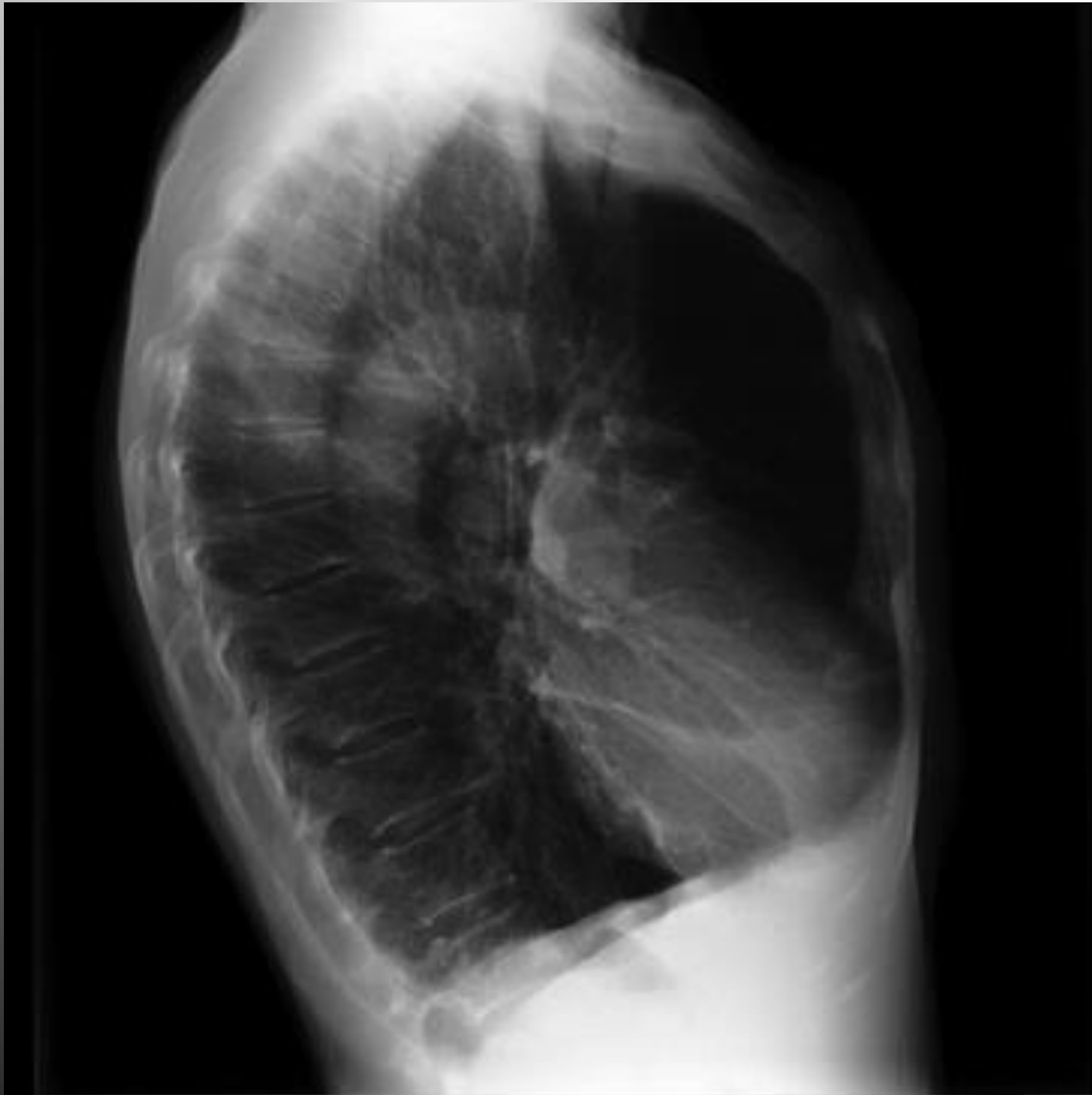
R

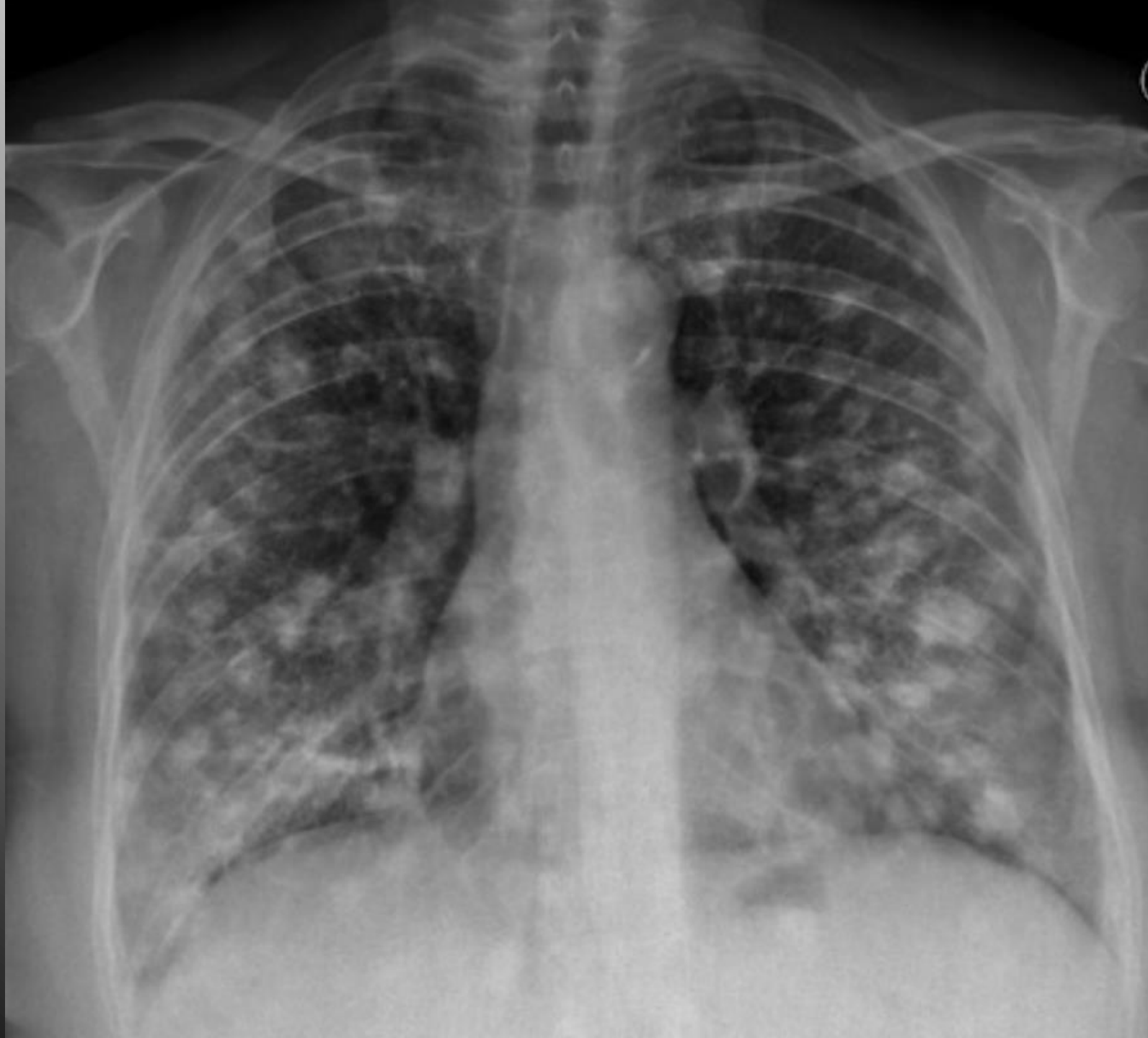

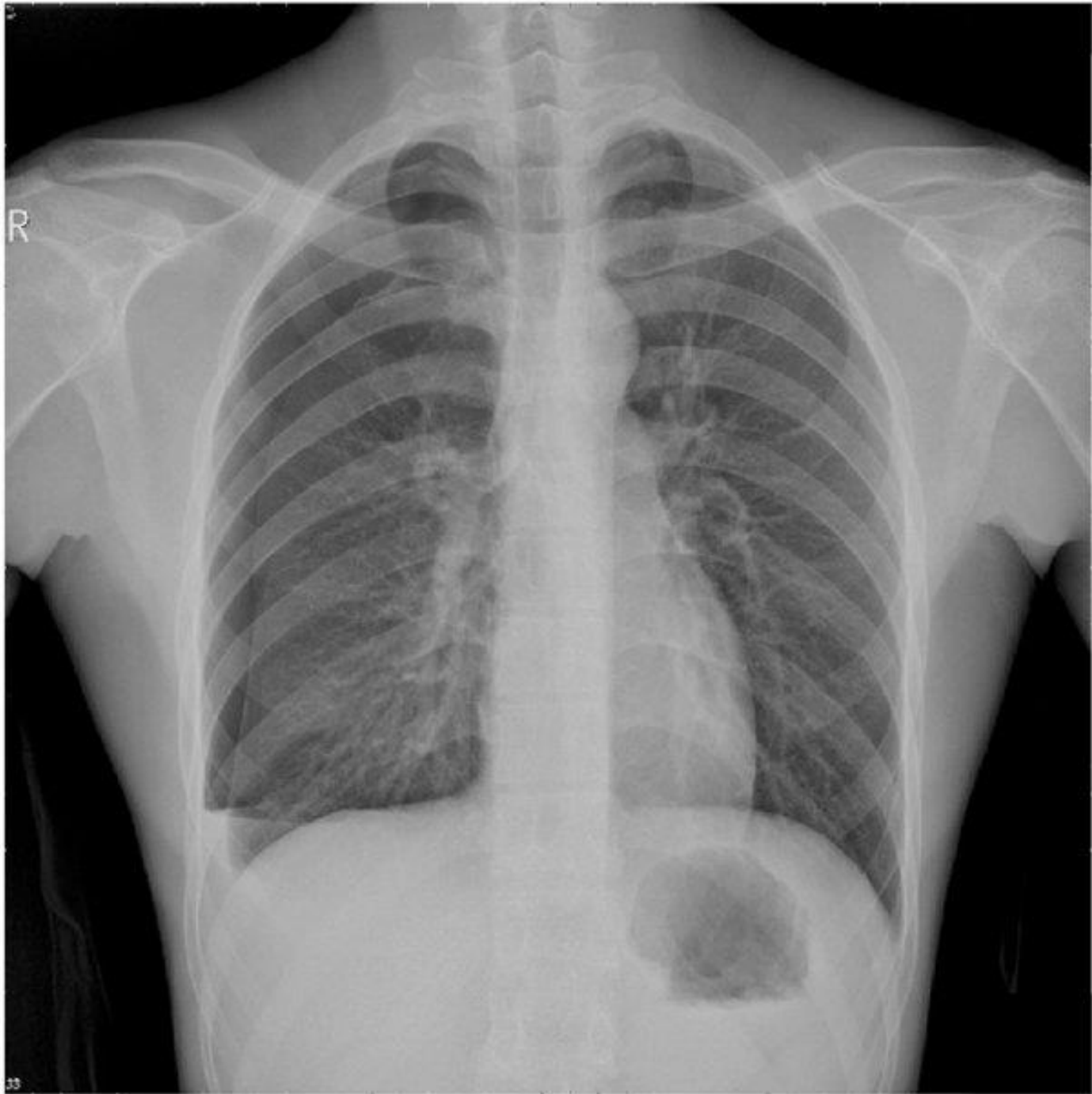


L
DEB

AF







**Remember... not everything is
always “black and white”**

Thanks for listening

Tim.Gilmore@lsuhs.edu